

## Antifibrogenic effect in vivo of low doses of insulin-like growth factor-I in cirrhotic rats

Begoña Muguerza <sup>a</sup>, Inma Castilla-Cortázar <sup>a,b,\*</sup>, María García <sup>a,b</sup>, Jorge Quiroga <sup>c</sup>,  
Santiago Santidrián <sup>a</sup>, Jesús Prieto <sup>c</sup>

<sup>a</sup> Department of Physiology, School of Medicine and Liver Unit, University of Navarra, 31080 Pamplona, Spain

<sup>b</sup> Department of Physiology, School of Medicine, University of Málaga, 29080 Málaga, Spain

<sup>c</sup> Department of Internal Medicine, School of Medicine and Liver Unit, University of Navarra, 31080 Pamplona, Spain

Received 27 November 2000; received in revised form 5 March 2001; accepted 22 March 2001

### Abstract

Insulin-like growth factor-I (IGF-I) is produced mainly in the liver and it induces beneficial effects on the nutritional status, the liver function and oxidative hepatic damage in cirrhotic rats. The aim of this work was to analyze the effect of IGF-I on mechanisms of fibrogenesis in cirrhotic rats. Liver cirrhosis was induced by CCl<sub>4</sub> inhalation and phenobarbital in Wistar rats. Ten days after stopping CCl<sub>4</sub> administration (day 0), rats received either IGF-I (2 µg/100 g bw/day) (CI+IGF) or saline (CI) subcutaneously during 14 days. Animals were sacrificed on day 15. As control groups were used: healthy rats (CO) and healthy rats treated with IGF-I (CO+IGF). Liver histopathology, hydroxyproline content, prolyl hydroxylase activity, collagen I and III mRNA expression and the evolution of transformed Ito cells into myofibroblasts were assessed. Among the two control groups (CO+IGF), no differences were found in hydroxyproline content and these levels were lower than those found in the two cirrhotic groups. Compared with untreated cirrhotic rats, the CI+IGF-I animals showed a significant reduction in hydroxyproline content, prolyl hydroxylase activity and collagen α1(I) and α1(III) mRNA expression. A higher number of transformed Ito cells (α-actin +) was observed in untreated cirrhotic animals as compared to CO and CI+IGF groups. In summary, treatment with IGF-I reduced all of the studied parameters of fibrogenesis. In conclusion, low doses of IGF-I induce in vivo an antifibrogenic effect in cirrhotic rats. © 2001 Elsevier Science B.V. All rights reserved.

**Keywords:** Liver cirrhosis; Insulin-like growth factor-I; Fibrogenesis; Ito cell; Hydroxyproline; Prolyl hydroxylase; Malondialdehyde; Oxidative stress

### 1. Introduction

Cellular damage and regeneration with fibrogenesis are processes involved in the development of liver cirrhosis [1,2]. Liver fibrosis is characterized by a marked accumulation of extracellular material, especially interstitial collagen (types I and III) [3], and this process is a result of increased collagen synthesis [3,4]. Collagen synthesis depends on mRNA expres-

Abbreviations: IGF-I, insulin-like growth factor-I; rhIGF, recombinant human insulin-like growth factor; MDA, malondialdehyde; TGF-β, transforming growth factor-β; HGF, hepatocyte growth factor

\* Corresponding author, at address b. Fax: +34-95-213-1650; E-mail: icastill@uma.es

sion as well as the enzymatic activities such as prolyl hydroxylase (EC 1.14.11.2; proline 2-oxoglutarate dioxygenase) [5,6]. On the other hand, it is known that Ito cells transformed into myofibroblast are the most important cellular source of hepatic fibrosis [6].

Insulin-like growth factor-I (IGF-I) is a growth factor with anabolic effects [7], which is mainly produced by hepatocytes. Patients with advanced liver cirrhosis show low serum concentrations of this hormone [8–12]. Previous works have shown beneficial effects of low doses of IGF-I on experimental cirrhosis (nutritional status [13], malabsorption [14–16], osteopenia [17] and hypogonadism [18]) including liver function tests and oxidative liver damage [19]. This growth factor has been considered a potential factor involved in fibrogenesis both *in vitro* and *in vivo* [20–26]. The reported role for IGF-I as stimulator of Ito cell proliferation *in vitro* and the observation of increased expression of IGF receptors during the process of fibrogenesis support this opinion [20–26].

We have previously shown that the administration of low doses of IGF-I to CCl<sub>4</sub>-cirrhotic rats improves liver function and reduces fibrosis [19]. To gain more insight into the mechanisms behind the hepatoprotective effects of IGF-I, we have explored the effect of this treatment on mechanisms leading to fibrosis. Hence, histopathology, evaluation of transformed Ito cells into myofibroblasts, hydroxyproline content, prolyl hydroxylase activity and collagen types I and III mRNA expression were assessed.

## 2. Materials and methods

### 2.1. Induction of liver cirrhosis

All the experimental procedures were performed in conformity with the Guide for the Care and Use of Laboratory Animals (7th edn., National Academy Press, Washington, DC). Forty-eight male Wistar rats (3 weeks old, weighing about 130–150 g) were used for this study. Twenty-four of them were randomly allocated to two control groups. Liver cirrhosis was induced in the remaining 24 rats by inhalation of CCl<sub>4</sub> (Merck, Darmstadt, Germany). The organic solvent was administered twice a week, with a progressively increasing exposure time, ranging from 1 to 5 min, during an 11 week period as

previously described [14,19]. To accelerate the development of cirrhosis, phenobarbital (Luminal, Bayer, Leverkusen, Germany) was added to drinking water (400 mg/l) beginning 1 week before the first CCl<sub>4</sub> exposure and throughout the entire period of cirrhosis induction [27]. Animals were housed in cages placed in a room with a 12 h light–darkness cycle and constant humidity and temperature (20°C). Both food (standard semipurified diet for rodents, purchased from B.K. Universal, Sant Vicent dels Horts, Spain) and water were given *ad libitum*. Healthy control rats (CO) were subjected to the same protocol excluding phenobarbital administration and CCl<sub>4</sub> exposure.

### 2.2. Study design

Ten days after stopping CCl<sub>4</sub> administration, the study period was initiated. Rats were randomly assigned to receive either vehicle (saline) (group CI, *n* = 12) or recombinant human (rh) IGF-I (2 µg IGF-I/100 g bw/day, in two divided doses) (group CI+IGF, *n* = 11) subcutaneously for 14 days. Healthy rats were also randomly assigned to receive vehicle (CO, *n* = 12) or IGF-I (CO+IGF-I, *n* = 12) at the same dosage as the CI+IGF group.

Animals were sacrificed by decapitation 24 h after administering the last dose. Livers were dissected out. Tissue sample from the left major liver lobe was processed (fixed in Bouin solution) for histological examination. Tissue specimens were immediately frozen by immersion in liquid N<sub>2</sub> and stored at –80°C.

The inclusion criteria for the study were established cirrhosis with fibrous septa delimiting regenerative nodules. None of the cirrhotic rats in this series had ascites.

### 2.3. Histological degree of fibrosis and hydroxyproline content

In liver sections stained with Masson's trichrome, semiquantitative assessment of fibrosis was blindly performed using a numerical scoring system based on the number, length and thickness of fibrous septa as previously described [19] that explored the whole preparation. The length of the septa (examined at 80× magnification) was assessed as follows: 1 point,

minimal grade fibrosis that can be observed in normal livers; 4 points, septa confluent between portal tracts and between portal tracts and central veins; and 2 or 3 points, intermediate lengths of septa observed. The width of the fibrous septa was calculated at  $150\times$  magnification, scoring 4 points when the mean value of the thickness of nine septa (three periportal, three perivenous and three perinodular) was 75–55  $\mu\text{m}$ , 3 points when it was 55–40  $\mu\text{m}$  and 2 points when it was approx. 40–30  $\mu\text{m}$ . The number of septa was scored as 4 points when there were numerous septa extending into the nodules, thus dissecting a small number of hepatocytes forming micronodules, 2–3 points when septa penetrating into nodules were less numerous surrounding bigger nodules, and 1 point when there was no formation of micronodules inside macronodules. Each preparation (four fields, at magnifying lens) was evaluated by two different observers, receiving a maximum of 12 points each time. The arithmetic mean of the two scores was taken as the final score.

Liver hydroxyproline levels were determined as a rough index of collagen content by multiplying the hydroxyproline content by the factor 7.46 [28]. Briefly, 50 mg aliquots of liver tissue were hydrolyzed for 22 h at  $110^\circ\text{C}$  in 6 N HCl, and hydroxyproline content was quantified by HPLC using the Pico-Tag method (Waters, Milford, MA, USA) for amino acid analysis (coefficient inter- and intraassay variation = 1% and 0.05% respectively; detection limits < 40 pmol). Hydrolysate, 25  $\mu\text{l}$ , was derivatized with phenyl isothiocyanate at pH 9–10 to produce phenyl thiocarbamyl amino acid derivatives. After derivatization, samples were dried under vacuum and redissolved with 0.01 M disodium hydrogen phosphate in acetonitrile (pH 7.4). Finally, samples were introduced into a  $300\times 3.9$  mm HPLC chromatographic column (Waters), with a 10  $\mu\text{m}$  particle stationary phase, at  $46^\circ\text{C}$ . An automatic injection system was used to introduce samples in the column. As a mobile phase, 70 mM sodium acetate in acetonitrile/methyl alcohol/water (45:45:10) pH 6.46 was used. Commercially available standard amino acid solutions were processed similarly, and used as external standard to calculate hydroxyproline concentrations in the experimental samples.

Hydroxyproline content was expressed as  $\mu\text{mol/mg}$  liver protein. Liver protein concentration was deter-

mined in liver tissue homogenates by Bradford's method [29].

#### 2.4. Enzymatic activity of prolyl hydroxylase

Prolyl hydroxylase was measured in liver homogenates by the method of Hutton et al. [30] with slight modifications as described previously [31]. This method measures the tritiated water formed when tritiated proline (40 Ci/mmol, New England Nuclear, Boston, MA, USA) present in a 3,4 (*n*) proline-labeled polypeptide substrate is hydroxylated to hydroxyproline. Briefly, this technique involves the homogenization of the frozen liver sample in a solution of sucrose 0.25 M, EDTA 10  $\mu\text{M}$ , dithiothreitol 1 mM, 50  $\mu\text{g/ml}$  phenylmethylsulfonyl fluoride, 0.1% (w/v) Triton X-100, and 50 mM Tris-HCl buffer (pH 7.2) at  $4^\circ\text{C}$ , in an Elvehjem-Potter apparatus. The incubation was carried out with 200  $\mu\text{l}$  of the aliquots of the supernatants that were centrifuged at  $500\times g$  for 5 min, 150  $\mu\text{l}$  [ $^3\text{H}$ ]proline-labeled substrate prepared in isolated chick embryo connective tissue and 800  $\mu\text{l}$  Tris-HCl buffer (pH 7.2), containing 1 mM ferrous ammonium sulfate, 2 g/l denaturalized bovine serum albumin, 0.4 g/l catalase ( $2\times 10^6$  u/l), 2 mM  $\alpha$ -ketoglutarate, 0.1 mM dithiothreitol, and 50 mM ascorbic acid. The reaction was incubated aerobically for 30 min at  $30^\circ\text{C}$  and stopped with 100  $\mu\text{l}$  of 50% trichloroacetic acid. The tritiated water produced was separated by vacuum distillation and counted in a scintillation counter. A blank obtained by the addition of homogenization buffer instead of sample was used in each determination. Prolyl hydroxylase activity in each homogenate and blank was measured in duplicate. Total protein concentrations in homogenates were measured by the method of Bradford [29]. The results were expressed as cpm/mg protein.

#### 2.5. RNA extraction and hybridization

RNA extraction was performed by homogenization in 4 M guanidinium thiocyanate followed by phenol chloroform extraction. The RNA was spectrophotometrically measured and 25  $\mu\text{g/lane}$  were then analyzed by formaldehyde agarose electrophoresis and transferred by capillary blotting to nylon filters (Gene Screen, New England Nuclear). Ethid-

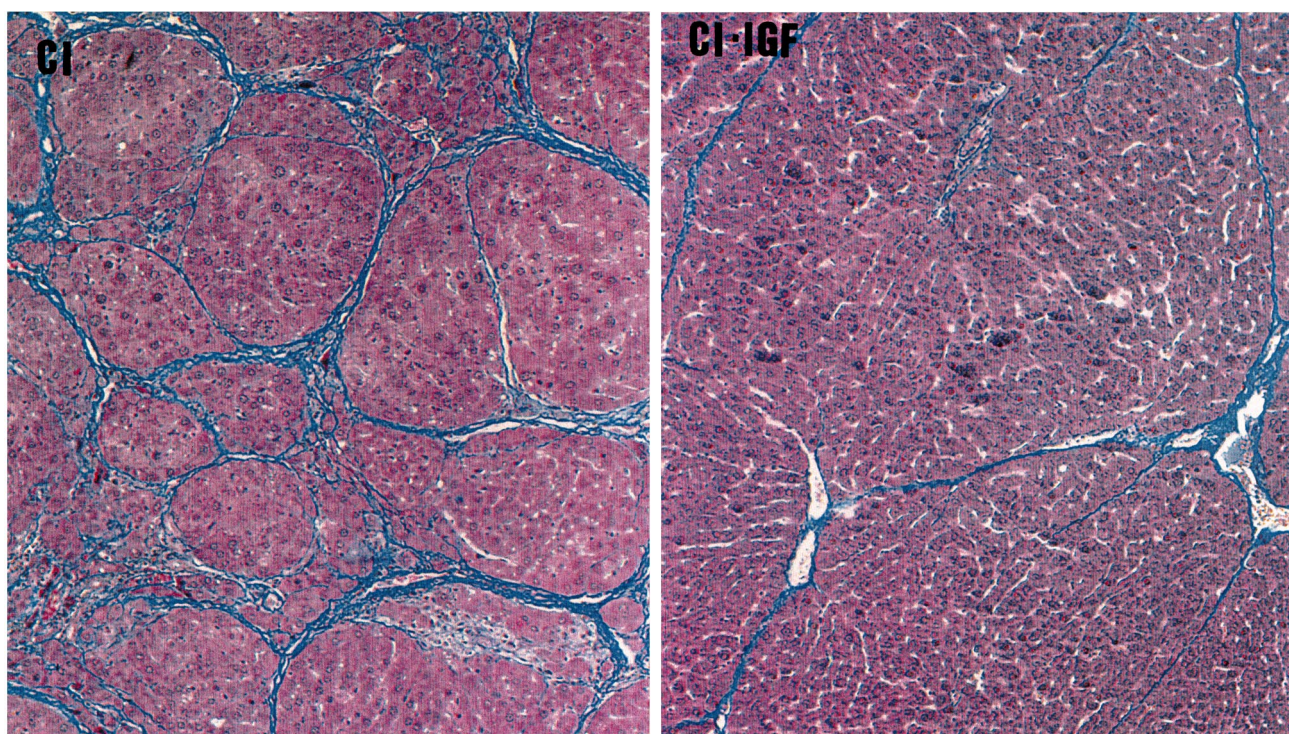


Fig. 1. Histopathologic findings in liver biopsy (4  $\mu$ m section; Masson's trichrome stain; original magnification 150 $\times$ ) from: CI, untreated cirrhotic rat; CI+IGF, cirrhotic rat treated with IGF-I. Liver hydroxyproline content in these two animals was 4.71 and 3.66  $\mu$ g/mg protein for CI and CI+IGF, respectively.

ium bromide staining was used to assess the relative amount and the intact nature of the RNA. Subsequent probing of the Northern blot hybridizations was performed using cDNAs  $^{32}$ P-labeled by random priming using a commercially available kit (Amersham, UK). The cDNAs used include GADPH as an internal control,  $\alpha$ 1(I) collagen and  $\alpha$ 1(III) collagen. Nylon membranes were prehybridized and hybridized at 42 $^{\circ}$ C in 50% formamide containing 6 $\times$ SSC, 50 mM sodium phosphate pH 7.0, 1 mM EDTA, 1 $\times$ Denhardt's solution, 50  $\mu$ g/ml sheared single-stranded salmon sperm DNA, and 10% dextran sulfate. Prehybridization was performed for 4 h and hybridization for 16 h in the presence of 1 $\times$ 10 $^6$  cpm/ml cDNA. All the blots were washed under stringent conditions at 65 $^{\circ}$ C. Autoradiograms were developed using Kodak XAR-5 film and intensifying screens at -80 $^{\circ}$ C. After each hybridization step, the blot was washed with 50% formamide in 1 $\times$ SSC at 75 $^{\circ}$ C for 45 min to remove the probe.

Quantification was performed on scanned X-ray films of Northern blots corrected by GADPH mRNA in the same RNA preparations.

### 2.5.1. Immunostaining for $\alpha$ -actin

When injured, liver Ito cells assume a fibroblast-like morphology expressing  $\alpha$ -actin. These transformed cells produce large amounts of collagen. Immunohistochemical staining of  $\alpha$ -actin in paraffin sections (4  $\mu$ m) was performed using an avidin-biotin peroxidase technique as described by Shu et al. [32] with a few modifications. The primary antibody anti- $\alpha$ -actin was obtained from Bio Genex Laboratories (San Roman, USA). Negative controls were performed by omission of the antigen retrieval procedure. The positive staining was estimated blindly in the entire preparation using a numerical score from 1 to 4 points as follow: 1 point, staining exclusively localized in smooth muscle, around the vessels that can be observed in normal livers; 4 points, large lines of immunostaining along the fibrous septa; 2 or 3 points, little stain deposition or intermediate lengths of lines, respectively.

### 2.6. Statistical analysis

Data are expressed as mean ( $\pm$ S.E.M.). To assess

the homogeneity among the different groups of rats a Kruskal–Wallis test was used, followed by multiple post-hoc comparisons using Mann–Whitney *U* tests with Bonferroni adjustment. A regression model was fitted considering malondialdehyde (MDA) concentration and prolyl hydroxylase activity as the dependent and independent variables, respectively. Any *P* value less than 0.05 was considered to be statistically significant. Calculations were performed with SPSSW in v.6.0. program.

### 3. Results

#### 3.1. Liver histology and liver hydroxyproline content

All rats from groups CI and CI+IGF showed, at the end of the study, micronodular or macromicronodular cirrhosis. The histological score of fibrosis was significantly lower in CI+IGF than in CI ( $9.1 \pm 0.5$  vs.  $10.4 \pm 0.2$ ;  $P < 0.05$ ) (Fig. 1). In accordance with this observation, hydroxyproline content ( $\mu\text{mol}/\text{mg}$  protein) was also significantly lower in hydroxyproline cirrhotic rats treated with IGF-I than in CI animals ( $3.2 \pm 0.3$  vs.  $3.8 \pm 0.3$ ,  $P < 0.05$ ) and significantly higher in these two groups than in healthy controls ( $0.7 \pm 0.1$ ,  $P < 0.01$ , both) (Fig. 2A).

Similar values were found for the two control groups (CO+IGF =  $0.69 \pm 0.06$   $\mu\text{mol}$  hydroxyproline/mg protein). Accordingly, no histopathological findings were observed in the CO+IGF group. Therefore, no further mechanisms leading to fibrosis were studied in this group.

#### 3.2. Prolyl hydroxylase activity

High hepatic levels of prolyl hydroxylase activity (cpm/mg protein) were observed in CI rats as compared with controls (CI =  $76.75 \pm 5.75$ ; CO =  $32.73 \pm 2.22$ ;  $P < 0.01$ ). However, this enzymatic activity was significantly reduced in CI+IGF as compared with untreated cirrhotic rats (CI+IGF =  $66.76 \pm 6.38$ ;  $P < 0.05$ ) (Fig. 2B).

#### 3.3. Expression of mRNAs coding for type I and III collagens

The expression of mRNAs coding for  $\alpha 1(\text{I})$  and

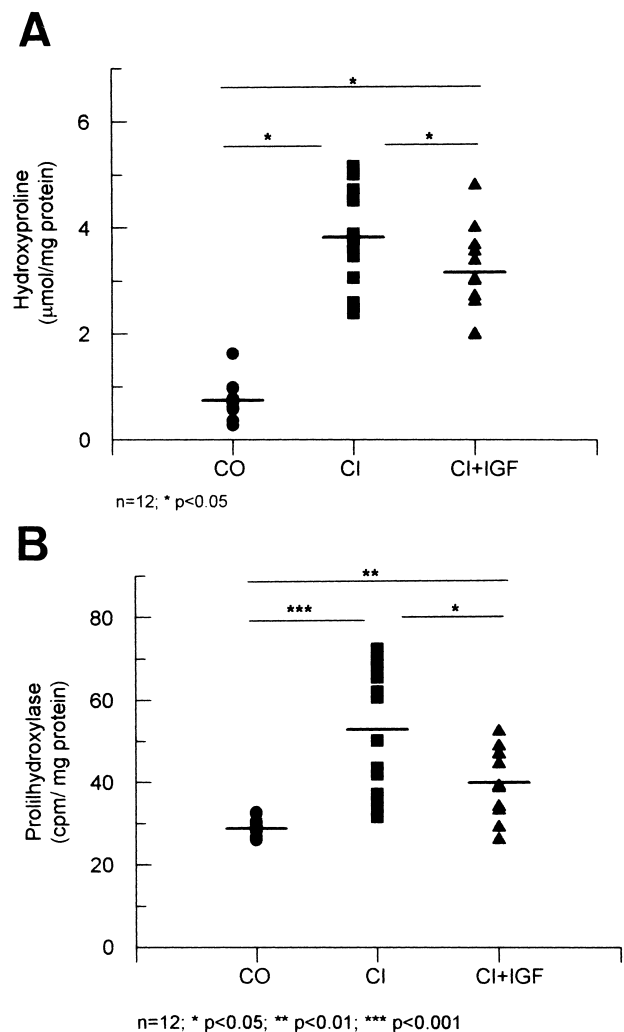


Fig. 2. (A) Liver hydroxyproline content, in the three main experimental groups: CO, healthy controls; CI, untreated cirrhotic group; CI+IGF, cirrhotic animals treated with IGF-I. (B) Activity of prolyl hydroxylase (cpm/mg protein) in the three groups. Hepatic levels of prolyl hydroxylase activity were higher in untreated cirrhotic rats (CI) than in controls (CO) ( $P < 0.01$ ). This enzymatic activity was significantly reduced in cirrhotic animals treated with IGF-I (CI+IGF) as compared with CI ( $P < 0.05$ ). \* $P < 0.05$ , \*\* $P < 0.01$ , \*\*\* $P < 0.001$ .

$\alpha 1(\text{III})$  chain collagens was investigated by Northern blot. The absorbance values scanned from X-ray films of Northern blots were corrected for GADPH mRNA used as blot control (collagen  $\alpha 1(\text{I})$ ): CO =  $2.20 \pm 0.43$ ; CI =  $5.87 \pm 1.10$ ; CI+IGF =  $3.75 \pm 0.53$ ,  $P < 0.01$  CO vs. cirrhotic groups, and  $P < 0.05$  CI vs. CI+IGF group; and collagen  $\alpha 1(\text{III})$  CO =  $5.51 \pm 1.02$ ; CI =  $33.93 \pm 5.54$ ; CI+IGF =  $24.50 \pm 4.93$ ,

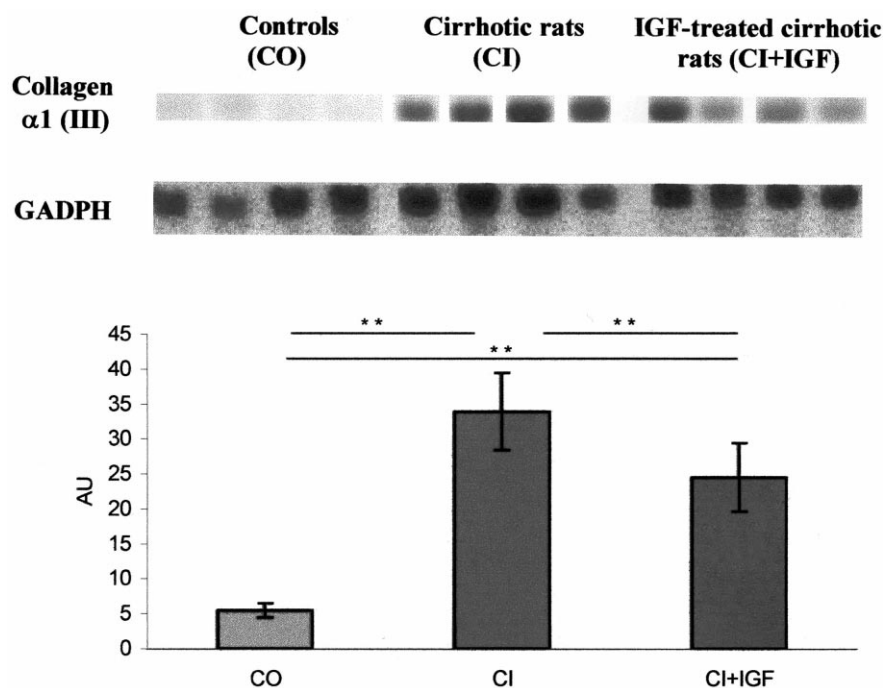


Fig. 3. Northern blot analysis: levels of collagen  $\alpha 1(I)$  mRNA in liver from healthy controls (CO,  $n=12$ ), untreated cirrhotic rats (CI,  $n=12$ ) and the cirrhotic group treated with IGF-I (CI+IGF,  $n=11$ ). Expression of collagen  $\alpha 1(I)$  was 2.67-fold higher in the CI group than in the CO group, and 1.70-fold in CI+IGF animals. \* $P < 0.05$ , \*\* $P < 0.01$ .

$P < 0.01$  CO vs. cirrhotic groups, and  $P < 0.05$  CI vs. CI+IGF animals). As shown in Figs. 3 and 4, there were differences in the expression of  $\alpha 1(I)$  and  $\alpha 1(III)$  collagens in both cirrhotic groups as compared to the CO group. However, the expression of these mRNAs was lower in the CI+IGF-I group than in the CI group. The same filters were successively hybridized with  $\alpha 1(I)$  and  $\alpha 1(III)$  collagen cDNA. Thus, the values are not directly comparable.

### 3.4. Immunohistochemistry for $\alpha$ -actin

The hepatic distribution of  $\alpha$ -actin, as a marker of myofibroblasts, was performed using immunohistochemistry, because myofibroblasts are considered the most important source of collagen [6,33,34]. In liver sections from all CO animals,  $\alpha$ -actin immunostaining was localized exclusively in myocytes, surrounding the vessels (Fig. 5, CO, score:  $1.0 \pm 0.0$ ). In the livers from the CI group immunostaining was also found in the fibrous septa and in many instances these were confluent (between portal tracts and around the central veins), and the immunostaining was as strong as in myocyte cells (Fig. 5, CI,

score:  $2.7 \pm 0.3$  points). However,  $\alpha$ -actin immunostaining was much lower in the CI+IGF than in the CI group (Fig. 5, CI+IGF, score:  $2.1 \pm 0.2$ ). Semiquantitative scoring for  $\alpha$ -actin showed significant differences between controls and cirrhotic groups ( $P < 0.001$ ) and between untreated and IGF-treated rats ( $P < 0.05$ ).

### 3.5. Lipid peroxidation index: correlation between malondialdehyde and prolyl hydroxylase activity

In order to find a relationship between parameters of fibrogenesis and oxidative liver damage, MDA, an index of lipid peroxidation [35,36], was assessed as described in a previous work [19]. Hepatic levels of MDA (nmol/g tissue) were increased in CI rats as compared with the control group (CI =  $158 \pm 35$ ; CO =  $40 \pm 3$ ;  $P < 0.01$ ) and as was previously reported in a similar protocol [19], this marker of lipid peroxidation was again significantly reduced in CI+IGF as compared with CI (CI+IGF =  $57 \pm 6$  nmol/g tissue,  $P < 0.01$ ). A significant and direct correlation between hepatic MDA and prolyl hydroxylase activity was found ( $r = 0.57$ ,  $P < 0.01$ ).

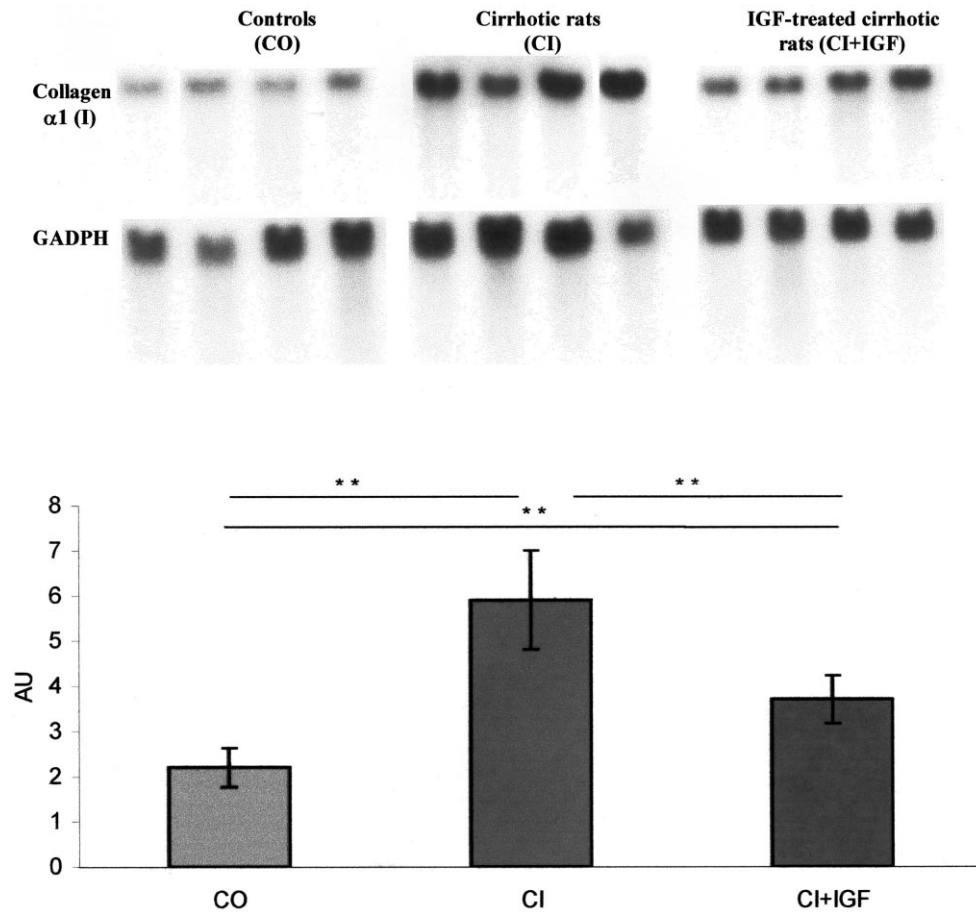


Fig. 4. Northern blot analysis: levels of collagen  $\alpha 1$ (III) mRNA in liver from healthy controls (CO,  $n=12$ ), untreated cirrhotic rats (CI,  $n=12$ ) and the cirrhotic group treated with IGF-I (CI+IGF,  $n=11$ ). Expression of collagen  $\alpha 1$ (III) was 6.16-fold higher in the CI group and 4.44-fold in the CI+IGF animals, than in the CO group.  $*P < 0.05$ ,  $**P < 0.01$ .

#### 4. Discussion

This study shows that several mechanisms leading to fibrogenesis in rats with  $\text{CCl}_4$ -induced cirrhosis are reduced with low doses of IGF-I over a 2 week period. These mechanisms, such as prolyl hydroxylase activity, transformation of Ito cells into myofibroblasts and mRNA expression of the most abundant types ( $\alpha 1$ (I) and  $\alpha 1$ (III)) of collagen, appear to be relevant in the development of fibrosis in the liver. In fact, the histopathological scores of fibrosis and hydroxyproline content were lower in cirrhotic rats treated with IGF-I than in untreated cirrhotic animals.

In a previous protocol, we reported similar histological findings [19]. The above mentioned work suggested hepatoprotective effects on the liver in cirrhotic rats which received a short-term course of

IGF-I. We observed a decrease in lipid peroxidation associated with an increase of antioxidant enzyme activities in hepatic tissue [19]. Interestingly enough, the present study demonstrates that IGF-I not only decreases hepatic collagen content as was previously shown [19], but also its synthesis, reducing both prolyl hydroxylase activity and collagen mRNA expression.

Although the mechanism of IGF-I action remains hypothetical, the present study provides evidence of the antifibrogenic effect in vivo of IGF-I, at these low doses. This antifibrogenic effect exerted by IGF-I in the  $\text{CCl}_4$  model of liver cirrhosis seems to be related to the antioxidant activities displayed by this hormone.

Much evidence has been accumulated in recent years supporting the hypothesis that oxidative stress plays a major role in the pathogenesis of liver injury.

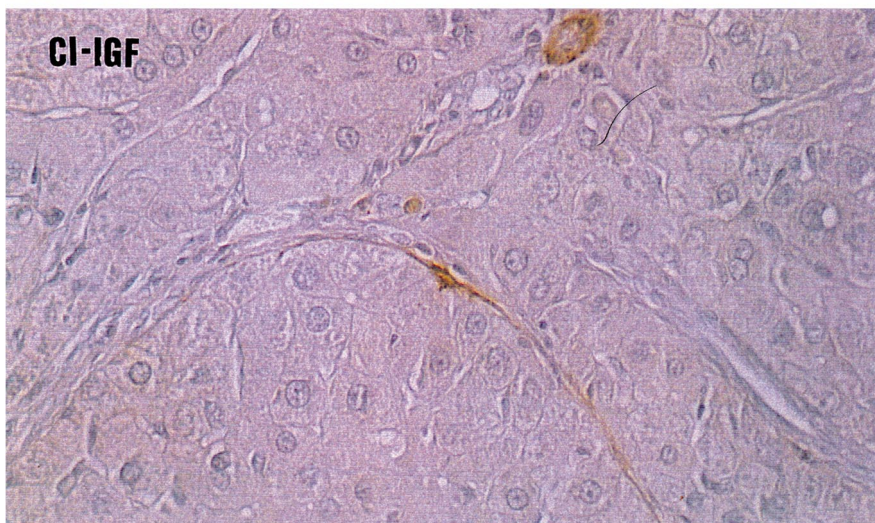
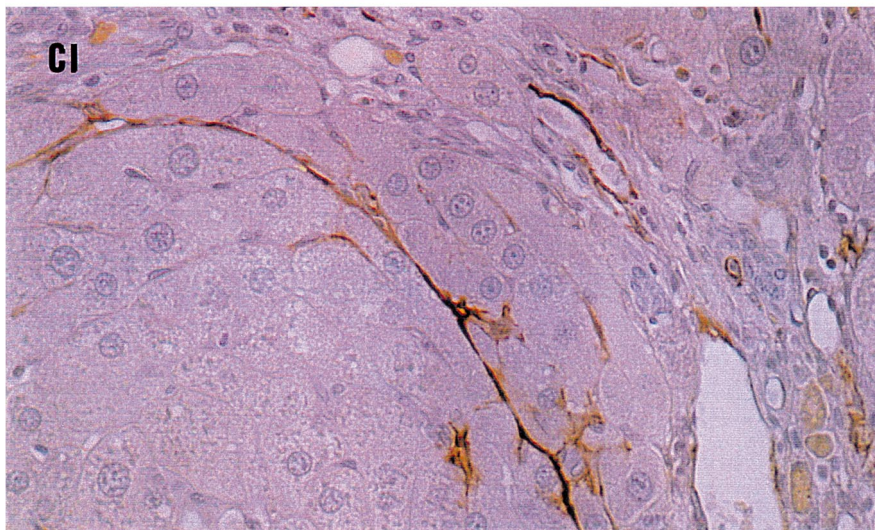
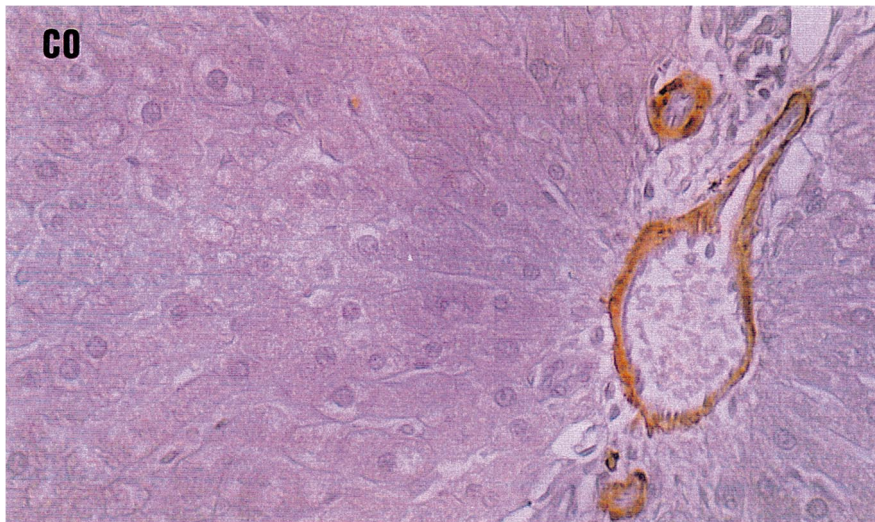




Fig. 5. Immunohistochemistry for  $\alpha$ -actin in liver histologic sections (4  $\mu$ m). The immunostaining was focused around the vessel in healthy controls (CO). More extensive zones were stained in untreated cirrhotic animals (CI), suggesting a major number of Ito cells transformed into myofibroblasts ( $P < 0.01$  vs. CO). The stain for  $\alpha$ -actin was significantly less in the cirrhotic group treated with IGF-I (CI+IGF,  $P < 0.05$  vs. CI group).

Although a causal relationship between oxidative damage and hepatocellular injury still remains a matter of debate [37–42], *in vitro* experiments have demonstrated that lipid peroxidation can cause cytopathic changes and trigger gene transcription [37]. Lipid peroxidation seems to upregulate the expression and synthesis of fibrogenic cytokines [44]. It has been shown that lipid peroxidation products stimulate the expression of collagen genes in myofibroblasts [37,45] and the activity of hepatic prolyl hydroxylase [38,43]. The activation of hepatic stellate cells is mediated by oxidative stress [43]. Ito cells are perisinusoidal cells thought to be a major source of collagen in normal and fibrotic livers [6]. These cells (isolated in culture or in injured liver) assume a fibroblast-like morphology expressing  $\alpha$ -actin. These transformed cells produce large amounts of procollagen type I and also type III [6,47].

In the present study, a higher hepatic lipid peroxidation, expression of collagen mRNAs, prolyl hydroxylase activity, and hydroxyproline content were found in untreated cirrhotic rats as compared to cirrhotic animals treated with IGF-I. In addition, a more extensive  $\alpha$ -actin staining was present in the livers from the untreated cirrhotic group.

The diminution of mRNA collagen was observed in both collagen  $\alpha 1$ (I) and  $\alpha 1$ (III). In untreated cirrhotic animals the expression of collagen  $\alpha 1$  type I was 2.67 times higher than in the controls and it was only 1.7 times that in treated cirrhotic animals. Collagen  $\alpha 1$  type I is the most important component of extracellular matrix in the cirrhotic liver [6,46]. In addition, the expression of collagen  $\alpha 1$  type III was 6.16 times higher in untreated cirrhotic animals than in controls and only 4.44 times higher in CI+IGF rats.

Because prooxidant hepatocellular injury and resulting fibrogenesis occur in a diversity of human liver diseases [9,11,46], and the mentioned previous data indicated that IGF-I, at low doses, protects the liver against oxidative damage [19], this antioxidant mechanism of IGF-I could explain the antifibrogenic

actions described in the present study. These findings are in apparent opposition with the reported role of IGF-I as a stimulator of Ito cell proliferation *in vitro* [20–26] and with the observation of increased expression of IGF receptors during the process of fibrogenesis [25].

A problem in interpreting these data is the reported low expression of IGF-I receptors in hepatocytes that makes it difficult to explain the biological action of IGF-I in this tissue. However, there are some data that may contribute to clarify this point. Regenerating hepatocytes express IGF-I receptors [50] and in addition we have recently observed a reduction in GHR mRNA levels in the liver of cirrhotic rats and – interestingly – a higher expression after IGF-I treatment [51]. Improved responses of the liver parenchyma to GH could be behind the effects of IGF-I treatment [51].

On the other hand, several works have reported that IGF-I induces hepatocyte growth factor (HGF) production by liver cells [48]. Since HGF may have important roles in liver regeneration and induces anabolic effects on cirrhotic liver [48,49], the described beneficial actions of IGF-I could be secondary to HGF synthesis. In fact, transduction with HGF gene suppressed the increase of transforming growth factor- $\beta 1$  (TGF- $\beta 1$ ), which plays an essential part in the progression of liver cirrhosis, inhibited fibrogenesis and hepatocyte apoptosis, and produced the complete resolution of fibrosis in the cirrhotic liver, thereby improving the survival rate of rats with this severe illness [49]. The mechanism that couples these two growth factors (HGF and IGF-I) remains to be elucidated.

In summary, this study demonstrates that the administration of IGF-I, at low doses, *in vivo*, not only decreases hepatic collagen deposition but also its production, acting as an antifibrogenic agent at two levels: decreasing prolyl hydroxylase activity and mRNA expression of collagen. This work provides new evidence of the beneficial effect of IGF-I supplementation in experimental liver cirrhosis. These re-

sults provide an experimental basis for further studies aiming at exploring the potential of IGF-I in the treatment of human cirrhosis.

### Acknowledgements

The authors wish to thank Dr. Dan Edwall from Pharmacia and Upson for providing rhIGF-I used in this study; Mr. Guillermo Ezpeleta, from the Department of Pathology of the Hospital of Navarra, for his help in histological analysis of liver specimens; and the ‘Gobierno de Navarra’, Mr. J. Celaya, Mr. I. Sanz and ‘Fundación Echébano’ for financial collaboration. Finally, we are deeply indebted to Mrs. M.P. Redin and C. Chocarro for their expert secretarial and technical assistance. This study was supported by the Program ‘I+D, Comisión Interministerial de Ciencia y Tecnología (CICYT), Gobierno de España’, SAF 99/0072.

### References

- [1] H.O. Conn, C.E. Atterbury, in: L. Schiff, E.R.J. Schiff (Eds.), *Cirrhosis*, Lippincott, Philadelphia, PA, 1987, pp. 725–864.
- [2] M. Rojkind, M.A. Giambrone, L. Biempica, *Gastroenterology* 76 (1979) 710–719.
- [3] D.M. Bissel, S.L. Friedman, J.J. Maher, F.J. Roll, *Hepatology* 11 (1990) 488–498.
- [4] J. Risteli, K.I. Kivirikko, *Biochem. J.* 144 (1974) 115–122.
- [5] K.I. Kivirikko, R. Myllylä, *Ann. NY Acad. Sci.* 460 (1985) 187–201.
- [6] F.R. Weiner, M.A. Giambrone, M.J. Czaja, A. Shah, G. Annoni, S. Takahashi, M. Eghbali, M.A. Zern, *Hepatology* 11 (1990) 111–117.
- [7] J.I. Jones, D.R. Clemmons, *Endocr. Rev.* 1 (1995) 3–34.
- [8] R.M. Schimpf, D. Lebec, M. Donadieu, *Acta Endocrinol.* 86 (1977) 355–362.
- [9] N. Hattori, H. Kurahachi, K. Ikekubo, T. Ishihara, K. Moridera, M. Hino, Y. Saiki, H. Imura, *Metab. Clin. Exp.* 41 (1992) 377–381.
- [10] S. Møller, U. Becker, A. Juul, N.E. Skakkebaek, E. Christensen, and EMALD Group, *Hepatology* 23 (1996) 1073–1078.
- [11] S. Møller, M. Gronbaek, K. Main, U. Becker, N.E. Skakkebaek, *J. Hepatol.* 17 (1993) 315–320.
- [12] A. Caufriez, P. Reding, D. Urbain, J. Goldstein, G. Copin-schi, *J. Endocrinol. Invest.* 14 (1991) 317–321.
- [13] A. Picardi, A. Costa de Oliveira, B. Muguerza, A. Tosar, J. Quiroga, I. Castilla-Cortázar, S. Santidrián, J. Prieto, *J. Hepatol.* 24 (1996) 267–279.
- [14] I. Castilla-Cortázar, A. Picardi, J. Ainzua, A. Tosar, E. Urdaneta, M. Pascual, M. García, J. Quiroga, J. Prieto, *Am. J. Physiol. Gastrointest. Liver Physiol.* 276 (1999) G37–G42.
- [15] I. Castilla-Cortázar, J. Prieto, E. Urdaneta, M. Pascual, M. Núñez, E. Zudaire, M. García, J. Quiroga, S. Santidrián, *Gastroenterology* 113 (1997) 1180–1187.
- [16] A. Pascual, I. Castilla-Cortázar, E. Urdaneta, J. Quiroga, M. García, A. Picardi, J. Prieto, *Am. J. Physiol. Gastrointest. Liver Physiol.* 279 (2000) G319–G324.
- [17] A. Cemborain, I. Castilla-Cortázar, M. García, J. Quiroga, B. Muguerza, A. Picardi, J. Prieto, *J. Hepatol.* 28 (1998) 122–131.
- [18] I. Castilla-Cortázar, M. García, J. Quiroga, N. Diez, F. Diez-Caballero, A. Calvo, M. Diaz, J. Prieto, *Hepatology* 31 (2000) 592–600.
- [19] I. Castilla-Cortázar, M. García, B. Muguerza, J. Quiroga, R. Pérez, S. Santidrián, J. Prieto, *Gastroenterology* 113 (1997) 1682–1691.
- [20] R.H. Goldstein, C.F. Poliks, P.F. Pilch, B.D. Smith, A. Fine, *Endocrinology* 124 (1989) 964–969.
- [21] M. Pinzani, H.E. Abboud, D.C. Aron, *Endocrinology* 127 (1990) 2343–2349.
- [22] A.M. Gressner, A. Brenzel, T. Vossmeier, *Liver* 13 (1993) 86–94.
- [23] E.M. Zimmermann, R.B. Sartor, R.D. McCall, M. Pardo, D. Bender, K. Lund, *Gastroenterology* 105 (1993) 399–409.
- [24] A.M. Gressner, B. Lahme, A. Brenzel, *Hepatology* 22 (1995) 1507–1518.
- [25] A. Brenzel, O.H. Weiner, A.M. Gressner, in: K. Wake, E. Wisse, D.L. Knook (Eds.), *Cells of the Hepatic Sinusoid*, vol. 5, The Kupffer Cell Foundation, Leiden, 1995, pp. 386–389.
- [26] G. Svegliati-Baroni, F. Ridolfi, A. Di Sario, A. Casini, L. Marucci, G. Gaggiotti, P. Orlandoni, G. Macarri, L. Perego, A. Benedetti, F. Folli, *Hepatology* 29 (1999) 1743–1751.
- [27] K. Chatamra, E. Proctor, *Br. J. Exp. Pathol.* 62 (1981) 283–288.
- [28] J. George, G. Chandrakasan, *Biochim. Biophys. Acta* 1292 (1996) 215–222.
- [29] M.M. Bradford, *Anal. Biochem.* 72 (1976) 248–254.
- [30] J.J. Hutton, A.L. Tappel, S. Underfriend, *Anal. Biochem.* 16 (1966) 384–394.
- [31] M. Torres-Salinas, A. Parés, J. Caballería, W. Jiménez, D. Heredia, M. Bruguera, J. Rodés, *Gastroenterology* 90 (1986) 1241–1246.
- [32] S.Y. Shu, G. Ju, L.Z. Fan, *Neurosci. Lett.* 85 (1988) 169–171.
- [33] M.G. Bachem, D. Meyer, R. Melchior, K.-M. Sell, A.M. Gressner, *J. Clin. Invest.* 89 (1991) 19–27.
- [34] A.M. Gressner, M.G. Bachem, *Ann. Biol. Clin.* 52 (1994) 205–226.
- [35] J.M.C. Gutteridge, *Clin. Chem.* 41 (1995) 1819–1828.
- [36] H. Esterbauer, R.J. Schaur, J. Zollner, *Free Radic. Biol. Med.* 11 (1991) 82–128.

- [37] P. Bedossa, K. Houglum, C. Trautwein, A. Holstege, M. Chojkier, *Hepatology* 19 (1994) 1262–1271.
- [38] S. Yamada, M. Yamada, Y. Murawaki, C. Hirayama, *Biochem. Pharmacol.* 40 (1990) 1015–1029.
- [39] R. Nordmann, C. Ribiere, H. Rouach, *Free Radic. Biol. Med.* 12 (1992) 219–240.
- [40] B.G. Rosser, G.J. Gores, *Gastroenterology* 108 (1995) 252–275.
- [41] J.M. McCord, *Clin. Biochem.* 26 (1993) 351–357.
- [42] C.S. Lieber, *Gastroenterology* 106 (1994) 1085–1105.
- [43] A.J. McCullough, in: W.G. Rector (Ed.), *Complications of Chronic Liver Disease*, Mosby Year Book Inc., St. Louis, MO, 1992, pp. 182–211.
- [44] A. Giménez, A. Parés, S. Alié, J. Camps, R. Deulofeu, J. Caballería, J. Rodés, *J. Hepatol.* 21 (1994) 292–298.
- [45] J. Camps, T. Bargallo, A. Gimenez, S. Alie, J. Caballeria, A. Parés, J. Joven, L. Masana, J. Rodés, *J. Clin. Sci.* 83 (1992) 695–700.
- [46] G. Poli, M. Parola, *Free Radic. Biol. Med.* 22 (1997) 287–305.
- [47] K.S. Lee, M. Buck, K. Houglum, M. Chojkier, *J. Clin. Invest.* 96 (1995) 2461–2468.
- [48] S. Skrtic, V. Wallenius, S. Ekberg, A. Brezel, A.M. Gressner, J.O. Jansson, *J. Hepatol.* 30 (1999) 115–124.
- [49] T. Ueki, Y. Kaneda, H. Tsutsui, K. Nakanishi, Y. Sawa, R. Morishita, K. Matsumoto, T. Nakamura, H. Takahashi, E. Okamoto, J. Fujimoto, *Nat. Med.* 2 (1999) 226–230.
- [50] J.F. Caro, J. Poulos, O. Ittoop, W.J. Pories, E.G. Flickinger, M.K. Sinha, *J. Clin. Invest.* 81 (1988) 976–981.
- [51] E. Mirpuri, E. García-Trevijano, I. Castilla-Cortázar, C. Berasain, J. Quiroga, C. Rodríguez-Ortigosa, J.M. Mato, J. Prieto, M.A. Avila, *Am. J. Physiol.* (2001) submitted for publication.