



- ◆ Trabajo realizado por el equipo de la Biblioteca Digital de la Fundación Universitaria San Pablo-CEU
- ◆ Me comprometo a utilizar esta copia privada sin finalidad lucrativa, para fines de investigación y docencia, de acuerdo con el art. 37 del T.R.L.P.I. (Texto Refundido de la Ley de Propiedad Intelectual del 12 abril 1996)

Treatment of traumatic anterior shoulder instability in the contact and collision athlete

Wiemi A. Dououguih

Purpose of review

Traumatic anterior instability is a common source of shoulder dysfunction in contact and collision athletes. There has been recent controversy surrounding the definitive treatment of this problem. The purpose of this review is to discuss recent advances in treatment of traumatic anterior shoulder instability.

Recent findings

Distinction has been made between contact and collision athletes and non-contact athletes because the former experience significantly more traumatic events per athletic exposure and are higher risk of sustaining an injury to the shoulder. The results of non-operative treatment of anterior instability tend to be poor. Overall, the rate of recurrence is estimated to be about 67%, with higher rates of recurrence in younger patients. Although some athletes may elect to return to play if the initial instability episode occurs during the season, definitive treatment involves surgical stabilization of the shoulder. Surgical treatment for this condition in contact and collision athletes sparks much debate, particularly with significant improvement in arthroscopic surgical techniques. Early reports showed high rates of failure with arthroscopic techniques. More recent evidence suggests that if performed under appropriate circumstances, both open and arthroscopic techniques have comparable results.

Summary

Participation in contact and collision sports places athletes at increased risk of recurrent traumatic anterior shoulder instability. Therefore, treating orthopaedists need to have an excellent understanding of anatomy, associated injuries, pathophysiology and current surgical techniques in order to effectively get players back on to the field.

Keywords

anterior, instability, athlete, shoulder

Introduction

Traumatic, anterior instability is a common source of shoulder dysfunction in contact and collision athletes. Distinction has been made between contact/collision athletes and non-contact athletes because the former experience significantly more traumatic events per athletic exposure and are at higher risk of sustaining an injury to the shoulder [1]. Anterior shoulder dislocations account for 90% of all dislocations about the shoulder. Such dislocations typically result from a fall onto an abducted externally rotated shoulder. The results of nonoperative treatment for anterior instability have been poor. Recurrence rates between 17–100% [2–5,6[•],7, 8[•]] have been reported with higher rates of recurrence in younger patients. Surgical stabilization of the shoulder is the gold standard, for definitive treatment of traumatic anterior instability in the contact and collision athlete [2–5,6[•],7, 8[•]].

Surgical treatment for this condition in contact and collision athletes sparks much debate particularly with significant improvement in arthroscopic surgical techniques. Early reports showed high rates of failure with arthroscopic techniques. More recent evidence suggests that if performed under appropriate circumstances both open and arthroscopic techniques have comparable results [9,10[•], 11–14[•],15–26]. Higher failure rates for surgery may be seen overall with contact and collision athletes [13,27]. Nevertheless, with proper understanding of surgical anatomy and tailoring surgery to appropriately address specific anatomic defects, good and excellent results predominate.

Normal functional anatomy of the shoulder

The shoulder is stabilized by a complex interaction between static and dynamic restraints. Because the glenohumeral joint has very limited bony contact area throughout its arc of motion, it relies more heavily on the surrounding soft tissues for stability than joints such as the hip or knee. The dynamic shoulder restraints include the rotator cuff, deltoid, biceps, and scapular stabilizing muscles. Static restraints include the superior, middle, and inferior glenohumeral ligaments, joint capsule, and rotator interval (Fig. 1). The inferior glenohumeral ligament is the most important structure in maintaining anterior instability [28]. The anterior band is felt to be the most important component of the inferior glenohumeral ligament in resisting an anteriorly directed force.

Pathophysiology

Bankart described the ‘essential lesion’ or a detachment of the anterior inferior glenoid labrum [29]. He found this

Curr Opin Orthop 16:82–88. © 2005 Lippincott Williams & Wilkins.

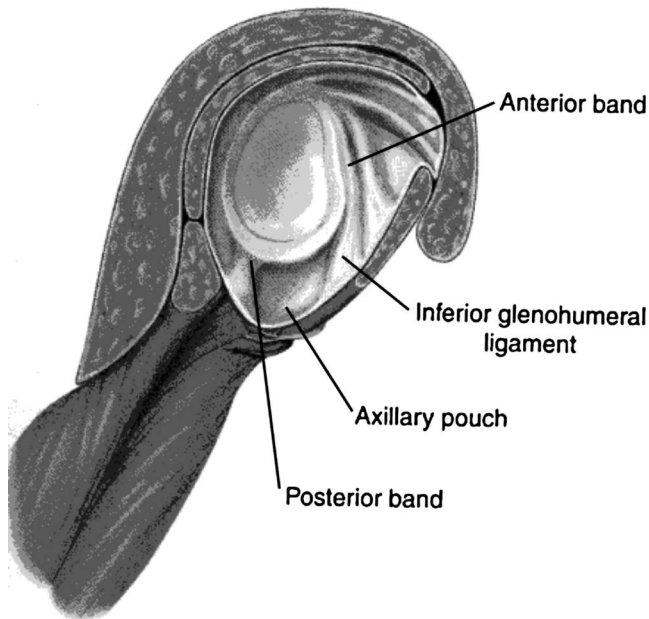
Coordinator, Sports Medicine Services, Department of Orthopaedic Surgery, Washington Hospital Center, Washington, DC, USA

Correspondence to Wiemi A. Dououguih, Coordinator, Sports Medicine Services, Department of Orthopaedic Surgery, Washington Hospital Center, 106 Irving St. NW, Suite 215, Washington, DC 20010, USA
Tel: 202 291 9266; fax: 202 291 7689; e-mail: Wiemi38@earthlink.net

Current Opinion in Orthopaedics 2005, 16:82–88

© 2005 Lippincott Williams & Wilkins.
1041-9918

Figure 1. Cut-away cross section displaying inferior glenohumeral ligament



This cut-away cross section displays the inferior glenohumeral ligament, the most important static restraint to anterior translation. The inferior glenohumeral ligament is composed of the anterior band, axillary pouch, and posterior band. Reprinted with permission from [7].

lesion to be associated with traumatic anterior instability in 100% of cases. It is now estimated that about 95% of traumatic anterior dislocations are associated with some form of the Bankart lesion. Less commonly the inferior glenohumeral ligament may be avulsed from the humerus. This humeral avulsion of the glenoid ligament (HAGL) has been reported to occur in 7–9% of anterior shoulder dislocations [30,31].

Although the Bankart lesion is considered requisite for development of traumatic anterior instability it does not appear to be sufficient itself to produce instability. This has been borne out by cadaveric studies in which simulation of a Bankart lesion alone did not produce anterior instability [7]. Moreover, clinical studies in which the glenohumeral ligaments were intentionally sectioned during capsular release for adhesive capsulitis have shown no incidence of iatrogenic shoulder instability [32*,33]. Plastic deformation of the capsule in association with detachment of the anterior inferior labrum seems to be the combination of pathology that leads to recurrent anterior instability.

Diagnosis

Athletes who have sustained an acute anterior dislocation will most likely report pain. They may be able to find a comfortable position for the arm in slight abduction and external rotation. A careful neurologic evaluation should be performed to rule out axillary nerve injury.

X-rays should include at a minimum AP and axillary views. Supplemental views may help reveal specific bony abnormalities. The West Point axillary and Garth views can help reveal bony Bankart lesions. An internal rotation AP or Stryker notch view can help identify a humeral head impression fracture. MR arthrography is a highly sensitive tool for identifying lesions of the labroligamentous complex. It can also help identify associated soft tissue injuries such as rotator cuff tears. Computed tomographic arthrography may be used in patients with contraindications to MRI and can help quantify the extent of previously cited bony lesions [34].

Treatment

Initial treatment of an acute traumatic anterior dislocation in the athlete should involve urgent reduction of the shoulder. Extended delays may make effective reduction more difficult. On-field reduction of the shoulder is controversial. Gentle manipulation maneuvers may be attempted by experienced practitioners. However, if there is any concern that reduction cannot be performed without creating further injury, attempts should be deferred until radiographs are obtained. Once radiographs have excluded a significant fracture the shoulder may be reduced with or without use of pain relievers and muscle relaxants. Recent evidence suggests that reduction of the dislocated shoulder after intra-articular injection of lidocaine is equivalent to reduction after use of intravenous sedation. It also may reduce hospital costs and decrease time spent in the emergency department [35].

The natural history of traumatic anterior shoulder dislocations in the athlete is poor. The mean rate for recurrent instability based on available reports is estimated to be 67% [9]. Recent reports estimate the average redislocation rate in athletes under the age of 20 to be between 75–100% [2,5,6**]. One recent study of 32 patients between the ages of 11 and 18 years showed a recurrence rate of 75% [6**]. Mean follow-up was 4 years (range 1–14). Objective outcome scores were well below normal (SANE 78.8, Rowe 78.6). The authors concluded that, untreated, traumatic anterior shoulder instability in this population causes significant functional morbidity. Others have, similarly, demonstrated that shoulder dislocation is not a benign event. Marx *et al.* [36] found that the risk of developing significant osteoarthritis requiring shoulder arthroplasty increased 10–20 times with a history of prior traumatic shoulder dislocation. Cameron *et al.* [37*] showed that there was a statistically significant increase in prevalence of osteoarthritis in patients who had a delay between the initial traumatic dislocation event and surgery ($P < 0.001$).

Conservative treatment after traumatic anterior dislocation has classically been thought to have little bearing on reducing the recurrence rates. Most papers show

recurrence rates between 25–90% [2,4,5,7,9,18]. However, recent evidence suggests that the position of immobilization may have a dramatic ability to reduce the rate of recurrent instability. Itoi *et al.* [38] demonstrated both in cadaveric specimens and by MRI that external rotation of the shoulder provides better coaptation of the anterior capsulolabral complex to the glenoid. Itoi *et al.* [39**] recently reported that no recurrent instability was found in patients who had undergone a 3-week period of immobilization in external rotation prior to institution of a physical therapy program for traumatic anterior instability. This was in comparison to a 30% rate of recurrence in patients treated with 3 weeks of immobilization in the conventional position of internal rotation. Longer-term study must be performed before any definitive conclusions can be made regarding the role of brief immobilization in external rotation after traumatic anterior dislocation as a definitive treatment modality.

Surgical management

By convention, open capsulolabral repair has been the gold standard treatment for traumatic anterior shoulder instability in the contact athlete. However, recent advances in our understanding of arthroscopic anatomy, surgical techniques, and increased quality of implants has led to the school of thought that arthroscopic instability repair may be comparable to open repairs in this population [10*,11,14**,15]. Arthroscopic labral repair using suture anchor techniques have a reported failure rate ranging from 4–38% [10*,11,14**,15,17,24–27]. Lower rates of failure in the open literature have been recently challenged, with more critical examination suggesting comparable failure rates for arthroscopic and open approaches [13,19].

Despite advances in arthroscopic stabilization, the most common complication of arthroscopic stabilization remains recurrent instability. Arthroscopic stabilization has evolved considerably since the first technique of staple fixation [40]. Techniques employing metal tacks, transglenoid suture, and bioabsorbable tacks and thermal capsulorrhaphy have largely fallen out of favor because of unacceptably high failure rates [7,18,41–44,45*,46–48].

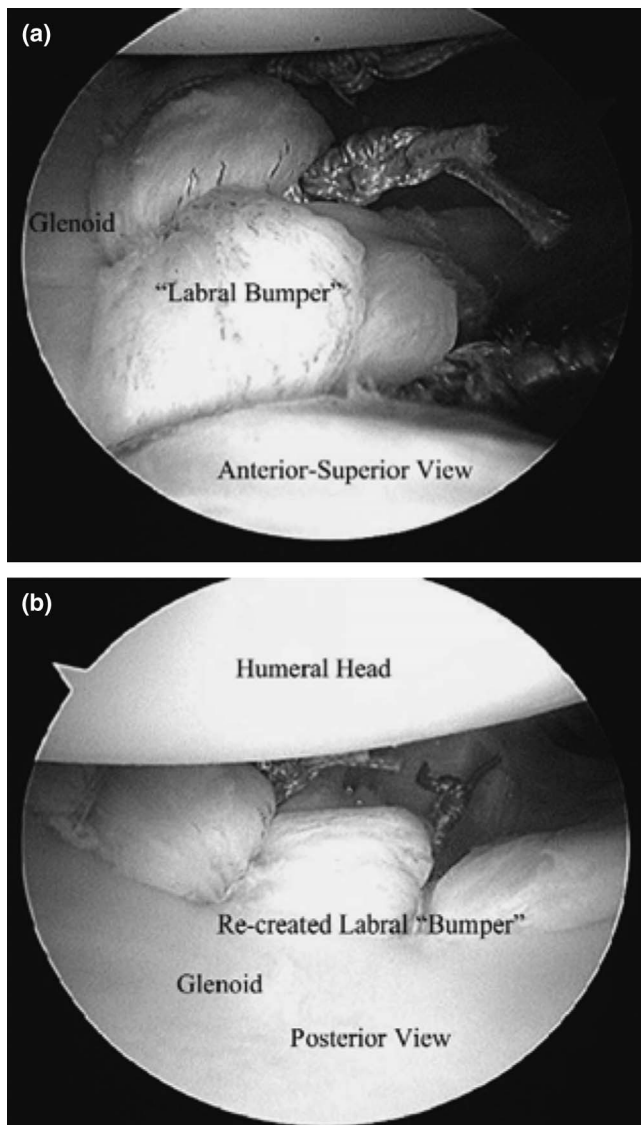
Suture anchors have all but replaced previous fixation devices for arthroscopic labral repair. Suture anchor repairs have shown the highest success rates of any technique for arthroscopic anterior instability repair. They allow for anatomic repair of labro-ligamentous lesions and enable the surgeon to concomitantly address capsular redundancy (Fig. 2) with excellent results in recent studies [10*,11,14**,15,25,26].

Open versus arthroscopic instability repair

Literature regarding the results of arthroscopic versus open stabilization for the collision or contact athlete is

conflicting. Some authors have reported higher incidence of recurrence after arthroscopic repair in young, male athletes participating in collision sports [10*,27,49]. However, other authors suggest that outcome in contact and collision athletes may be equivalent to open repair, if arthroscopic repair is avoided in the presence of an anterior inferior glenoid rim fracture involving >25–30%, or an engaging Hill-Sachs lesions [10*,11]. In general, most early arthroscopic studies have identified participation in contact or collision sports as a significant risk factor. One study involved 56 patients who underwent one of three different stabilization procedures for recurrent instability experienced during Australian Rules football [27]. At a mean follow-up of 29.4 months, arthroscopic suture repair yielded a 70% recurrence rate and repair with bio-degradable tacks a 38% recurrence rate; 75% of the recurrences resulted from minimal trauma. Open capsular shift with Bankart repair also resulted in a high (30%) recurrence rate, although half of these injuries were caused by violent trauma. The authors advocated open surgery for athletes participating in Australian Rules football. Yoneda *et al.* [49] cited a 1.2% redislocation rate in 83 athletes who underwent open Bankart repair with coracoid transfer augmentation. Their study population consisted of 67 contact athletes (Rugby, Football, Judo); 92% of contact athletes returned to their previous level of play. The authors did not consider painful subluxation as a failure of treatment. Other authors have re-examined the results of open repairs in contact and collision sports populations using more strict criteria for failure including painful subluxation events. In a recent study of 58 American football players (43 high school, 11 college, and 4 professional athletes) at an average follow-up of 37 months after open Bankart repair, no postoperative dislocations and two subluxations were reported, a recurrence rate of 3%. Fifty-two of the 58 patients (90%) returned to playing football for at least 1 year. Uhorchak *et al.* [13] recently evaluated a population of military athletes participating in collision sports that underwent open Bankart repairs and found a 3% redislocation rate. However, there was a 12% incidence of rare subluxation events and 8% incidence of multiple, painful recurrent subluxation. The overall recurrence rate was 23%. Magnusson *et al.* [19] also found an unusually high failure rate for open Bankart repairs. There was a 17% recurrence rate (5 re-dislocations and 3 significant subluxation events requiring revision surgery) during the 4- to 9-year follow-up period [19]. The authors emphasized the importance of longer-term follow-up to properly report outcomes of instability surgery. They also cite failure to identify postoperative subluxation events as a weakness of many previous open studies. The results of Uhorchak and Magnusson are in stark contrast to other reports of open repairs. It suggests that previous studies have been too loose in their definition of failures and that arthroscopic repairs may be being held to a higher standard, falsely elevating the rate of failure these repairs.

Figure 2. Labral 'bumper'



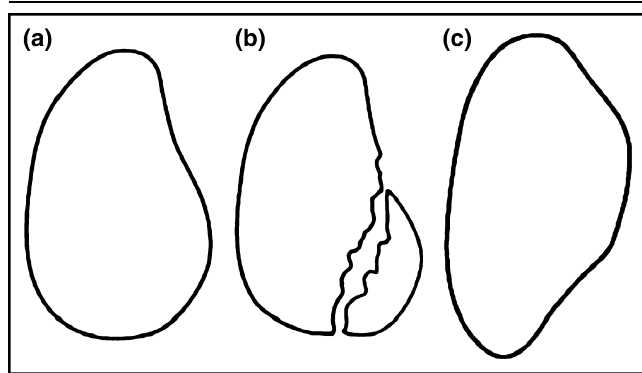
(a) Re-created labral 'bumper' viewed from the anterosuperior portal. Tension has been restored to the glenohumeral ligaments. (b) Labral 'bumper' viewing from the posterior portal. Reprinted with permission from [21].

Significant glenoid bone deficiency, an engaging Hill-Sachs lesion, the absence of a discrete Bankart lesion, and poor capsuloligamentous tissue quality have been associated with inferior outcomes following arthroscopic surgery. One recent study identified 101 contact athletes (96 South African rugby players and 5 American football players) from 194 patients with recurrent anterior instability. The rate of recurrence after arthroscopic Bankart repair with suture anchors was only 6.5% in the absence of glenoid deficiency or a Hill-Sachs lesion, but 89% in the presence of a significant bone defect. The authors concluded that the presence of an inverted pear-shaped glenoid (Fig. 3) or an engaging Hill-Sachs (Fig. 4) lesion

is a contraindication to arthroscopic repair [11]. They also concluded that the high reported recurrence rates among contact and collision sport athletes may actually be attributable to bony deficiency rather than their activities. Mazzoca *et al.* [14**] performed arthroscopic Bankart repair in 13 collision and 5 contact athletes. At minimum 2-year follow-up they reported an 11% redislocation rate and 15% recurrence rate. All athletes returned to organized high school or collegiate sports at the same level or higher. Another recent study in patients undergoing arthroscopic instability repair reported 95% good and excellent results with a 4% redislocation rate at 2- to 6-year follow-up; 90% of patients returned to their pre-injury level [10*]. Post-operative re-dislocation was significantly related to an osseous defect if the defect involved greater than 30% of the antero-inferior glenoid. A recent meta-analysis compared arthroscopic and open techniques [17]. Outcomes of 1946 patients in 45 arthroscopic repair series were compared with those of 724 patients in 14 open repair series. Comparison of the arthroscopic suture anchor repairs to open Bankart repairs showed no statistically significant difference in the rate of recurrence, although arthroscopically repaired patients who underwent arthroscopic repair had better external rotation.

For patients with large bony lesions of either the glenoid or the humeral head some authors believe a simple Bankart procedure whether arthroscopic or open may be predisposed to failure. In patients with significant bony deficiencies my preference is to perform an anatomic suture anchor repair with coracoid transfer augmentation. Yoneda looked at the results of this procedure exclusively in a population of collision and contact athletes. They reported a 1.2% re-dislocation rate [49]. When including all episodes of instability they had a 7% rate of recurrence overall. Allain *et al.* [16] looked at the results of the Latarjet procedure in 95 patients with a 10- to 23-year follow-up [16]. They reported no recurrent dislocations and two persistent subluxations (2% failure rate). Of 49 patients who participated in sports 40 returned to sports at the same level and five returned at a lower level. Of the 16 contact athletes, 11 returned to the same sport at the same level, three patients changed sports, and two returned to the same sport at a lower level. Although coracoid transfer has been associated with technique-specific complications including hardware failure and loss of external rotation, these occurrences are very low with proper technique. Failure to return to overhead throwing sports has been seen in high proportion of patients undergoing coracoid transfer procedures. These procedures should be avoided in patients who wish to resume overhead throwing postoperatively. Nevertheless, combining open anatomic soft-tissue repair with coracoid transfer augmentation is a durable, highly successful procedure that may be used for contact and collision athletes when recurrence is related to significant bony deficits.

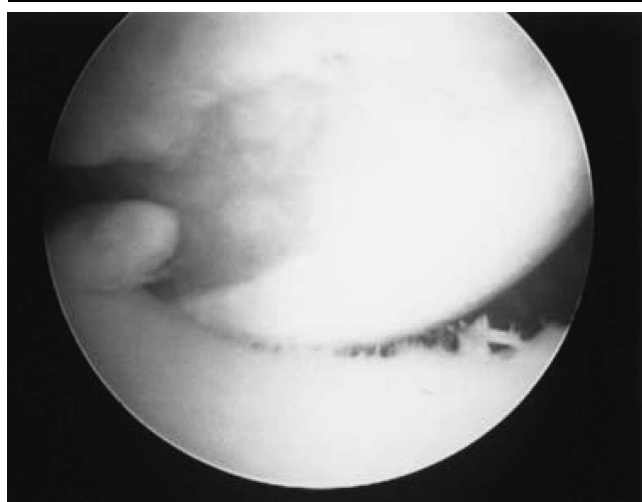
Figure 3. Normal pear-shaped glenoid and inverted pear glenoids



(a) The normal shape of the glenoid is that of a pear, larger inferiorly than superiorly. (b) A bony Bankart lesion can create an inverted pear glenoid configuration. (c) A compression Bankart lesion can also create an inverted pear glenoid. From [50*].

In summary, contact and collision athletes with a discrete Bankart lesion, a robust IGHL, minimal capsular laxity, and absence of other significant concomitant intra-articular pathology are appropriate candidates for arthroscopic repair. There is a higher likelihood of success when this procedure is properly performed by an experienced arthroscopist. If the surgeon adheres to rigid selection criteria, results are equivalent to those of open repair techniques. When arthroscopic repair is done in young, high-risk patients, patients with excessive capsular laxity and/or significant bone defects, failure of the repair may be more

Figure 4. Arthroscopic view of shoulder of a 22-year-old patient



Arthroscopic view of the shoulder of a 22-year-old patient who sustained over 50 subluxation events after initial traumatic anterior subluxation at the age of 19. Intra-operative, arthroscopic photograph shows a large engaging Hill-Sachs lesion. This is an absolute contraindication to arthroscopic instability repair.

likely. Open repair is recommended under these circumstances. For contact and collision athletes with significant bony injury, consideration should be given to open soft tissue repair with coracoid transfer augmentation.

Treatment of first-time dis-locators

Another important surgical consideration is whether to delay surgery or to immediately, surgically stabilize the first time dislocator. There is compelling evidence that delay in treatment can lead to worse outcomes [36,37]. An increased incidence of concomitant pathology may also be seen with recurrent dislocation, including glenoid rim fractures, Hill-Sachs lesions, and poor tissue quality. These factors, together with the high failure rate for conservative treatment has led many authors to move towards early stabilization of the athlete's shoulder. Kirkley *et al.* [9] prospectively compared the results of 40 skeletally mature athletes under the age of 30 who were divided evenly into an immediate arthroscopic stabilization group and a physical therapy group. The immediate stabilization group had a 15.9% redislocation rate compared with a 47% redislocation rate in the therapy group ($P = 0.03$). Disease-specific quality of life was also significantly higher in the surgical group.

There is limited information directly comparing immediate stabilization to delayed stabilization. One study compared the arthroscopic findings of first-time dis-locators to those with greater than 25 episodes of instability. Tissue quality was better in the first-time group and no bony lesions were seen. In the recurrent instability group 16% had glenoid rim fractures and 40% demonstrated Hill-Sachs lesions [51]. The incidence of recurrent instability was also lower in the immediate stabilization group. Despite the risks of recurrent subluxation or dislocation many contact and collision athletes choose to complete the current season before electing to undergo a shoulder stabilization procedure. The use of an on-field brace (e.g., Sully brace) can allow the player to return to high-level athletics with reduced morbidity. One recent study looked a population of 19 collision and 11 contact athletes [8**]. All patients were between 14 and 20 years old. The authors found that 26 of the 30 patients were able to complete their season after an initial traumatic anterior dislocation or subluxation. This included three contact athletes and one collision athlete; 19 patients who were able to return wore braces. All patients who wore braces reported subjective improvement in stability with the brace. Despite subjective improvement in stability, 37% experienced at least one recurrent episode of instability. Although a high rate of return to contact and collision sports can be achieved, there is a significant incidence of recurrent instability. The player attempting to return to play prior to surgical stabilization should be informed of the associated risks specifically as it relates to recurrent instability.

Conclusion

Participation in contact and collision sports places athletes at increased risk of shoulder injuries. Traumatic anterior shoulder instability is a commonly seen entity that can cause significant morbidity and lost playing time in this population. Orthopaedists treating these injuries must have an excellent understanding of anatomy, associated injuries, pathophysiology, and current surgical techniques to effectively get players back on to the field.

References and recommended reading

Papers of particular interest, published within the annual period of review, have been highlighted as:

- of special interest
- of outstanding interest

- 1 Dick RW. NCAA Injury Surveillance System Data, 1984–2004.
- 2 Henry JH, Genung. Natural history of glenohumeral dislocation revisited. *Am J Sports Med* 1982; 3:135–137.
- 3 Yoneda B, Welsh RP, Macintosh DL. Conservative treatment of shoulder dislocations in young males. *J Bone Joint Surg* 1982; 64B:254–255.
- 4 Aronen JG, Regan K. Decreasing the incidence of recurrence of first time anterior shoulder dislocations with rehabilitation. *Am J Sports Med* 1984; 12: 283–291.
- 5 Marans HJ, Angel KR, Schemitsch EH, *et al.* The fate of traumatic anterior dislocation of the shoulder in children. *J Bone Joint Surg* 1992; 74A:1242–1244.
- 6 Deitch JD, Mehlman CT, Foad SL, *et al.* Traumatic anterior dislocation in adolescents. *Am J Sports Med* 2003; 31:758–763.
Thirty-two patients aged 11 to 18 were evaluated to determine the rate of recurrent anterior shoulder instability after an initial, documented, anterior shoulder dislocation. There was a 75% rate of recurrence; 16 of the 32 patients had to undergo a shoulder stabilization procedure for persistent symptoms related to instability. SANE and Rowe shoulder scores were well below normal at an average of 4 years from the initial event. The authors concluded that left untreated traumatic, recurrent shoulder instability causes significant morbidity that persists well beyond the initial event.
- 7 Tibone JE, Savoie FH, Shaffer BS, eds. *Shoulder arthroscopy*. 1st ed. New York: Springer Verlag; 2003
- 8 Buss DD, Lynch GP, Meyer CP, *et al.* Non-operative management for in-season athletes with anterior shoulder instability. *Am J Sports Med* 2004; 32:1430–1433.
This study reported on 19 collision and 11 contact athletes between the ages of 14 and 20 years old who sustained an initial traumatic dislocation of the shoulder in-season. The authors found that 26 of the 30 patients were able to complete their season after an initial traumatic anterior dislocation or subluxation. This included three contact athletes and one collision athlete; 19 patients who were able to return wore braces. All patients who wore braces reported subjective improvement in stability with the brace. However, 37% experienced at least one recurrent episode of instability. Although this study demonstrates a high rate of return to contact and collision sports, it also demonstrates that recurrent instability occurs in a significant proportion of these players.
- 9 Kirkley A, Griffin, Richards C, *et al.* Prospective randomized clinical trial comparing the effectiveness of immediate arthroscopic stabilization versus immobilization and rehabilitation in first traumatic anterior dislocations of the shoulder. *Arthroscopy* 1999; 15:507–514.
- 10 Kim SH, *et al.* Arthroscopic anterior shoulder stabilization: 2 to 6 year follow-up. *J Bone Joint Surg* 2003, 85-A:1511.
This study reports a 4% redislocation rate. There were 95% good and excellent results. Postoperative re-dislocation related to a glenoid osseous defect of >30%; 90% returned to pre-injury level.
- 11 Burkhart SS, De Beer JF. Traumatic glenohumeral bone defects and their relationship to failure of arthroscopic Bankart repairs: significance of the inverted pear glenoid and the humeral head lesion. *Arthroscopy* 2000, 16:677–694.
- 12 Pagnani MJ, Dome DC. Surgical treatment of anterior shoulder instability in American football players. *J Bone Joint Surg* 2002, 84-A:711–715.
- 13 Uhorchak JM, Arciero RA, Huggard D, *et al.* Recurrent shoulder instability after open reconstruction in athletes involved in collision and contact sports. *Am J Sports Med* 2000; 28:794–799.
- 14 Mazzuca AD, Brown FM, Carreira DS. Arthroscopic anterior shoulder stabilization of collision and contact athletes. *Am J Sports Med* 2005; 33:52–60.
Arthroscopic repair of a Bankart lesion was performed in 18 contact and collision athletes (13 collision, 5 contact). Patients were re-evaluated at a minimum of 24 months. There was an 11% redislocation rate and a 15% recurrence rate. All athletes returned to play at the same or a higher level for at least one season. The authors concluded that arthroscopic Bankart repair was not contraindicated in contact and collision athletes.
- 15 Bacilla P, Field LD, Savoie FH III. Arthroscopic Bankart repair in a high demand patient population. *Arthroscopy* 1997; 13:51–60.
- 16 Allain J, Goutallier D, Lorion C. Long-term results of the Latarjet procedure for treatment of anterior instability of the shoulder. *J Bone Joint Surg* 1998, 80A:841.
- 17 Metcalf M, Savoie FH, Smith K. Meta-analysis of surgical reconstruction for anterior shoulder instability: a comparison of arthroscopic and open techniques. 21st Annual Meeting, Arthroscopy Association of North America; Washington, DC, April 27,2002.
- 18 Shaffer BS, Baublitz S. Acute shoulder injuries. In: Garrick JG, editor. *Orthopaedic knowledge update, sports medicine*. 3rd ed. American Academy of Orthopaedic Surgeons: Rosemont, Illinois; 2004
- 19 Magnusson L, Kartus J, Ejerhed L, *et al.* Revisiting the open Bankart experience. A four- to nine-year follow-up. *Am J Sports Med* 2002; 30:778–782.
- 20 Montgomery WH III, Jobe FW. Functional outcomes in athletes after modified anterior capsulolabral reconstruction. *J Sports Med* 1994; 22:352–358.
- 21 Ryu RKN. Arthroscopic approach to traumatic anterior shoulder instability. *Arthroscopy* 2003; 19 (suppl):94–101.
- 22 O'Neill DB. Arthroscopic Bankart repair of anterior detachments of the glenoid labrum: a prospective study. *J Bone Joint Surg* 1999, 81-A:1357–1366.
- 23 Gill TJ, Micheli LJ, Gebhard F, Binder C. Bankart repair for anterior instability of the shoulder: long-term outcome. *J Bone Joint Surg* 1997; 79A:850–857.
- 24 Mishra DK, Fanton GS. Two-year outcome of arthroscopic Bankart repair and electrothermal-assisted capsulorrhaphy for recurrent traumatic anterior shoulder instability. *Arthroscopy* 2001; 17:844–849.
- 25 Grana WA, Buckley PD, Yates CK. Arthroscopic Bankart suture repair. *Am J Sports Med* 1993; 21:348–353.
- 26 Tauro JC. Arthroscopic inferior capsular split and advancement for anterior and inferior shoulder instability: technique and results at 2- to 5-year follow-up. *Arthroscopy* 2000; 16:451–456.
- 27 Roberts SN, Taylor DE, Brown JN, *et al.* Open and arthroscopic techniques for the treatment of traumatic anterior shoulder instability in Australian rules football players. *J Shoulder Elbow Surg* 1999; 8:403–409.
- 28 O'Brien SJ, Neves MC, Arnoczky SP, *et al.* The anatomy and histology of the inferior glenohumeral ligament complex of the shoulder. *Am J Sports Med* 1990; 18:449–456.
- 29 Bankart ASB. Recurrent or habitual dislocation of the shoulder-joint. *BMJ* 1923; 2:1132–1133.
- 30 Schippinger G, Vasiliu PS, Fankhauser F, *et al.* HAGL lesion occurring after successful arthroscopic Bankart repair. *Arthroscopy* 2001; 17:206–208.
- 31 Wolf EM, Cheng JC, Dickson K. Humeral avulsion of glenohumeral ligaments as a cause of anterior shoulder instability. *Arthroscopy* 1995; 11:600–607.
- 32 Nicholson GP. Arthroscopic capsular release for stiff shoulders effect of etiology on outcomes. *Arthroscopy* 2003; 19:40–49.
Sixty-eight stiff shoulders were treated with arthroscopic capsular release. Five distinct etiologies were identified: postsurgical in 20, idiopathic in 17, post-traumatic in 15, diabetic in 8, and impingement syndrome (prior primary impingement developing stiffness) in 8. Average age was 50 years (range, 29–72), and follow-up averaged 3 years (range, 2–8). Prior to this procedure, duration of symptoms averaged 7.3 months (range, 3–48), and formal physical therapy averaged 3.7 months (range, 1–12). The study population showed significant improvement ($P < 0.0001$) for all outcome scores and active motion parameters. There were no complications related to the operation. Significant improvement was seen in all outcome measures. The time in physical therapy averaged 2.3 months (2–20 weeks) and time to attain final, pain-free range of motion averaged 2.8 months (1–6). There was no difference in time to final motion between the etiologic groups. The authors concluded that Arthroscopic capsular release was equally effective across the five identified etiologic groups, and provided significant pain relief, restoration of motion, and function within an average of 3 months.
- 33 Berghs BM, Sole-Molins X, Bunker TD. Arthroscopic release of adhesive capsulitis. *J Shoulder Elbow Surg* 2004; 13:180–185.
- 34 Sanders TG, Morrison WB, Miller MD. Imaging techniques for the evaluation of glenohumeral instability. *Am J Sports Med* 2000; 28:414–433.

- 35 Miller SL, Cleeman E, Auerbach J, Flatow EL. Comparison of intra-articular lidocaine and intravenous sedation for reduction of shoulder dislocations: a randomized prospective study. *J Bone Joint Surg* 2002; 84A:2135–2139.
- 36 Marx RG, McCarty, Montemurno DT, *et al.* Development of arthrosis following dislocation of the shoulder: a case control study. *J Shoulder Elbow Surg* 2002; 11:1–5.
- 37 Cameron ML, Kocher MS, Briggs KK. The prevalence of osteoarthritis in unstable shoulders. *Am J Sports Med* 2003; 31:53–55.
 This retrospective study involving 422 patients looked at the incidence of shoulder arthritis in patients with recurrent instability of the shoulder. The average time from injury to surgery was 1580 days in patients with osteoarthritis and the average time from injury to surgery was 802.1 days in patients without arthritis ($P < 0.001$). They concluded that the longer the patient's shoulder is unstable the more likely he or she will be to develop arthritis.
- 38 Itoi E, Sashi R, Minagawa H, *et al.* Position of immobilization after dislocation of the glenohumeral joint: a study with use of magnetic resonance imaging. *J Bone Joint Surg* 2001, 83-A:661–667.
- 39 Itoi E, Hatakeyama Y, Kido T, *et al.* A new method of immobilization after traumatic anterior dislocation of the shoulder: a preliminary study. *J Shoulder Elbow Surg* 2003; 12:413–415.
 This study included 40 patients that after initial dislocation of the shoulder were randomized to be treated in either internal rotation in a sling (conventional) or external rotation in a splint (10°). Minimum follow-up was 15.5 months. The recurrence rate in the group treated with internal rotation was 30%. There were no recurrences in the external rotation group. They concluded that immobilization in external rotation after shoulder dislocation is better than the conventional immobilization in internal rotation in terms of reducing recurrent dislocations.
- 40 Johnson L. Arthroscopic management for shoulder instability: stapling. Presented at the Arthroscopic Association of North America Specialty Day, Atlanta, Georgia; February 1988.
- 41 Wilkerson JP, Zvijac JE, Uribe JW, *et al.* Failure of polymerized lactic acid tacks in shoulder surgery. *J Shoulder Elbow Surg* 2003; 12:117–121.
- 42 Burkhart A, Imhoff AB, Roscher E. Foreign-body reaction to the bioabsorbable Suretac device. *Arthroscopy* 2000; 16:91–95.
- 43 Edwards DJ, Hoy G, Saies AD, *et al.* Adverse reactions to an absorbable shoulder fixation device. *J Shoulder Elbow Surg* 1994; 3:230–233.
- 44 Reinold MM, Wilk KE, Hooks TR, *et al.* Thermal-assisted capsular shrinkage of the glenohumeral joint in overhead athletes: a 15- to 47-month follow-up. *J Orthop Sports Phys Ther* 2003; 33:455–467.
- 45 D'Allessandro DF, Bradley JP, Fleischli, *et al.* Prospective evaluation of thermal capsulorrhaphy for shoulder instability. *Am J Sports Med* 2004; 32:21–33.
 These authors prospectively evaluated the efficacy of arthroscopic electrothermal capsulorrhaphy for the treatment of shoulder instability in 84 shoulders with an average follow-up of 38 months. Patients were divided into three subgroups: traumatic anterior dislocation (acute or recurrent), recurrent anterior anterior/inferior subluxation without prior dislocation, and multidirectional instability. Patients underwent arthroscopic thermal capsulorrhaphy after initial assessment, radiographs, and failure of a minimum of 3 months of nonoperative rehabilitation. Outcome measures included pain, recurrent instability, return to work/sports, and the American Shoulder and Elbow Surgeons (ASES) Shoulder Assessment score. Overall results were excellent in 33 participants (39%), satisfactory in 20 (24%), and unsatisfactory in 31 (37%). They concluded that because of the high failure rate associated with thermal capsulorrhaphy, widespread use should be tempered until further studies document its efficacy.
- 46 Fitzgerald BT, Watson BT, Lapoint JM. The use of thermal capsulorrhaphy in the treatment of multidirectional shoulder instability. *J Shoulder Elbow Surg* 2002; 11:108–113.
- 47 Selecky M, Vangsnest CT, Liao W-L, *et al.* The effects of laser-induced collagen shortening on the biomechanical properties of the inferior glenohumeral ligament complex. *Am J Sports Med* 1999; 27:168–172.
- 48 Miniaci A, McBirnie J. Thermal capsular shrinkage for treatment of multidirectional instability. *J Bone Joint Surg* 2003, 85-A:2283–2287.
- 49 Yoneda M, Hayashida K, Wakitani S, *et al.* Bankart procedure augmented by coracoid transfer for contact athletes with traumatic anterior shoulder instability. *Am J Sports Med* 1999; 27:21–26.
- 50 Lo IKY, Parten PM, Burkhart SS. The inverted pear glenoid: an indicator of significant glenoid bone loss. *Arthroscopy* 2004; 20:169–174.
 This cadaveric study was performed to determine the amount of bone loss required to produce an inverted pear glenoid. They found that the inverted pear glenoid was consistent with a loss of between 25–27% of bone from the anterior glenoid rim. They recommend bone grafting of the anterior glenoid to surgically restore stability to the glenohumeral joint.
- 51 Allegra F, Vincenzo C, Lodispoto F. Abstract: Anatomic lesion differences in first time dislocators compared with multiple dislocators: prospective study on arthroscopic Bankart repair. *Arthroscopy* 2003; 19(suppl 2):28.