



## Original Research

# A Comparison of the Efficacy of Two Omeprazole Formulations in the Treatment of Equine Gastric Ulcer Syndrome in Racehorses: A Blinded, Randomized Clinical Trial



Sara Busechian<sup>a,\*</sup>, Maria Beatrice Conti<sup>a</sup>, Micaela Sgorbini<sup>b</sup>, Giuseppe Conte<sup>c</sup>,  
 Maria Chiara Marchesi<sup>a</sup>, Camillo Pieramati<sup>a</sup>, Francesco Zappulla<sup>a</sup>, Valentina Vitale<sup>d</sup>,  
 Fabrizio Rueca<sup>a</sup>

<sup>a</sup> Department of Veterinary Medicine, Perugia, Italy

<sup>b</sup> Department of Veterinary Sciences, Pisa, Italy

<sup>c</sup> Department of Agricultural, Food and Agro-Environmental Sciences, Pisa, Italy

<sup>d</sup> Department of animal medicine and surgery, Veterinary teaching Hospital, University CEU Cardenal Herrera, C/ Santiago Ramón y Cajal, Valencia, Spain

## ARTICLE INFO

## Article history:

Received 25 January 2023

Received in revised form 18 March 2023

Accepted 23 March 2023

Available online 31 March 2023

## Keywords:

Equine

Gastro-resistant granules formulation

Powder paste formulation

Efficacy

ESGD

EGGD

## ABSTRACT

Equine gastric ulcer syndrome (EGUS) is the most common disease of the stomach in horses and treatment is based on the oral administration of omeprazole for at least 28 days. Aim of this study was to compare the efficacy of two formulations of oral omeprazole—powder paste and gastro-enteric resistant granules—in the treatment of naturally occurring gastric ulcers in racehorses. Thirty-two adult racehorses, aged between 2 and 10 years old, with clinical signs of EGUS were included in this blinded, randomized clinical trial. Two gastroscopies were performed to evaluate gastric lesions in the squamous or glandular mucosa before and after 28 days of treatment. After the first gastroscopy, 2/32 horses were excluded because affected by equine squamous gastric disease (ESGD) 1/4. The remaining horses were divided into 4 groups, and were treated with 2 formulations of omeprazole (gastroenteric resistant granules, group 1, or powder paste, group 3) or with 2 placebo formulations (granules, group 2, or paste, group 4). Treatments were performed in the placebo horses affected by ESGD or equine glandular gastric disease after the T28 gastroscopy control. No differences were found between groups at T0. Differences were found between T0 vs. T28 for granular ( $P = .002$ ) and powder paste ( $P = .01$ ) formulations. No differences were detected between the two groups receiving omeprazole formulations at T28 (0.34) and between T0 vs. T28 for either of the groups receiving placebo treatments. For all the variables, the size of the effect was greater than 0.5, proving that the treatments had a considerable effect. Gastro-enteric resistant granules and powder paste omeprazole showed similar efficacy in the treatment of ESGD. The glandular mucosa responded poorly to treatment with omeprazole.

© 2023 The Authors. Published by Elsevier Inc.

This is an open access article under the CC BY license (<http://creativecommons.org/licenses/by/4.0/>)

*Animal welfare/ethical statement:* The study was conducted according to Good Clinical Practices. The study was approved by the Italian Ministry of Health (D.Lgs 116/1992), and owner written/oral consent was obtained.

Conflict of interest statement: The study was sponsored by ACME s.r.l., Italy, ACME s.r.l. played no part in the collection and interpretation of the data or in the decision to submit the manuscript for publication.

The data of this study were not presented elsewhere and have not been sent for review to other Journals or Publications.

\* Corresponding author at: Sara Busechian, DVM, PhD, Department of Veterinary Medicine, University of Perugia, Via San Costanzo 4, 06129 Perugia, Italy.

E-mail addresses: [sara.busechian@unipg.it](mailto:sara.busechian@unipg.it), [sarabusechian@gmail.com](mailto:sarabusechian@gmail.com) (S. Busechian).

<https://doi.org/10.1016/j.jevs.2023.104296>

0737-0806/© 2023 The Authors. Published by Elsevier Inc. This is an open access article under the CC BY license (<http://creativecommons.org/licenses/by/4.0/>)

## 1. Introduction

Equine gastric ulcer syndrome (EGUS) is the most common disease of horse stomach particularly in sport horses, as well as in leisure horses, breeding mares and young horses [1–4]. There are two main forms of the disease in adult horses, one related to the squamous mucosa (ESGD) and the other to the glandular mucosa (equine glandular gastric disease [EGGD]) [3,4]. Prevalence for ESGD is high in all categories of horses, with the highest levels in racehorses, where up to 100% of animals have shown endoscopic signs of gastric lesions. EGGD seems to be less present than ESGD, but prevalence is still high in various horse populations [3,4].

The main cause of gastric ulcers in horses is the exposure of the stomach lining to low pH. This is due to the physiological continuous secretion of gastric acid during the day, which is not balanced by a continuous presence of feed in the stomach. Pathophysiology and risk factors seem to be different for ESGD and EGGD, but in both cases stress and poor management can reduce the amount of time horses spend eating [5,6].

Exercise has also been implicated in the development of ESGD, especially in racehorses, where it is associated with increased intra-abdominal pressure: this moves the acid content of the stomach toward areas of the squamous mucosa that are not normally exposed to low pH [6,7]. Clinical signs are usually unclear and non-specific (i.e., mild colic, exercise intolerance, weight loss, anorexia), but many horses show no symptoms despite having endoscopic lesions [3–5].

Treatment for both ESGD and EGGD is based on omeprazole (4 mg/kg PO once daily), with the addition of sucralfate in horses with EGGD (12 mg/kg PO twice daily) [3,4]. Omeprazole is available in different formulations registered for horses, for oral and parenteral administration, which have all proven to be safe and effective [8–13]. Sucralfate, on the other hand, is not registered for horses, and its use is generally off label, using human preparations.

Our aim was to compare the efficacy of two different omeprazole formulations (powder paste and gastro-enteric resistant granules) in the treatment of ESGD and EGGD in a cohort of 32 adult horses.

## 2. Materials and Methods

### 2.1. Animals

This was a randomized double-blind placebo-controlled study. A cohort of 32 athlete horses with clinical signs of ESGD/EGGD were investigated endoscopically for the presence of gastric lesions. The clinical symptoms observed were poor body condition score, dysorexia after racing, occasional diarrhea, poor performance, and recurrent mild colic. The study was approved by the Italian Ministry of Health (D.Lgs 116/1992), and owner written/oral consent was obtained.

The inclusion criteria were a diagnosis of ESGD with a score of at least 2/4, racehorses in race training and expected to remain in work, but not racing for the next four weeks, not receiving any medical treatment for EGUS or other diseases (i.e., NSAIDs) for at least three weeks before the inclusion and otherwise considered to be free of any other significant disease. Horses that presented any signs of systemic disease during any phase of the study were excluded. Both male and female horses were enrolled and were Thoroughbred and Trotters. The age ranged between 2 and 10 years, the body weight 300 to 600 kg and the BCS ranged between 3/9 and 5/9 [14].

### 2.2. Gastroscopy

Gastroscopy was performed before treatment (T0) and 28 days (T28) after the beginning of the omeprazole administration. The day before the first gastroscopy and after T28 gastroscopy, a clinical examination and routine blood work were performed on all the horses enrolled. The animals were then housed in 4 × 4 m boxes 15 hours before gastroscopy. Food was withheld 15 h and water 6h before the examination, respectively [15].

The examination was performed under sedation with detomidine (Domosedan, Vetquinol Italia) 40 to 80 µg/kg intravenously injected 15 minutes prior to the exam. Gastroscopy was performed using a processor (EPM-3300, Pentax Medical Italia) with a light Xenon 300 Watt and a 250 cm long scope (VBS-2900, Pentax Medical Italia) [16]. The gastroscopie was passed into the stomach,

which was insufflated with air through an air-flow system attached to the biopsy channel of the endoscope until the internal stomach folds appeared flattened. Feed material adherent to the nonglandular mucosa was flushed away with sterile water in order to visualize the entire nonglandular portion of the stomach, including the greater curvature, the lesser curvature, and the dorsal fundus. The images were digitally recorded for subsequent reevaluation and storage.

The lesions were graded and described in accordance with the ECEIM Consensus Statement guidelines [3]. ESGD lesions were scored using the scale in the Consensus Statement, while EGGD was qualitatively described as present or absent. Horses were considered positive for EGGD when they presented any kind of alterations of the mucosa, from reddening to erosions to ulcerations: localization and dimension of the lesions were recorded for each animal, but statistical analysis was performed considering only presence/absence of the disease [3]. The squamous and glandular mucosa were assessed separately for each horse. At T28, horses were considered responsive to treatment when they showed an improvement of the severity of ESGD of at least 1 point on the scale used [10]. The EGGD lesion response to treatment was defined as return of the mucosa to the normal appearance.

### 2.3. Treatment

After the T0 gastroscopy, of the 32 horses investigated, two subjects were excluded because they were affected by ESGD 1/4. The 30 horses affected by ESGD 2–4 were included in the study, 10 of these horses were also affected by EGGD. Once enrolled in the study, the horses were randomly allocated to a treatment group by pulling out the name from a hat. One investigator was responsible for randomization, while the remaining investigators remained blinded to the group allocation until scoring was completed and recorded. The owners were blinded to the treatment vs. placebo administration. The study protocol allowed for randomization to be broken in the event of an adverse event.

All the horses underwent similar feed, training, and management, and were fed twice daily with hay and grain: the morning feed was given within 2 hours of completing exercise, and the afternoon feed approximately 12 to 14 hours before exercising.

The horses were divided into four groups and treated as follows:

- Group 1 ( $n = 7$  horses): gastro-resistant granules of omeprazole were orally administered with a small amount of meal after 12 hours of fasting overnight at a dose of 4 mg/kg bw every 24 hour for 28 consecutive days.
- Group 2 ( $n = 7$  horses): placebo consisting of excipients present in the gastro-resistant granules of omeprazole was orally administered with a small amount of meal after 12 hours of fasting overnight, every 24 h for 28 consecutive days.
- Group 3 ( $n = 8$  horses): an omeprazole powder paste formulation was orally administered after 12 hours of fasting overnight directly in the mouth at a dose of 4 mg/kg bw every 24 hour for 28 consecutive days.
- Group 4 ( $n = 8$  horses): placebo consisting of excipients present in the omeprazole powder paste formulation was administered after 12 hours of fasting overnight per os directly in the mouth every 24 h for 28 consecutive days.

Sucralfate was not included in the treatment plan for horses with EGGD.

Immediately after the T28 gastroscopy, horses still suffering ESGD and/or EGGD were treated with omeprazole and, if necessary, sucralfate, at the recommended doses.

**Table 1**

Results on the equine squamous gastric disease (ESGD) scores and equine glandular gastric disease (EGGD) presence ("yes") or absence ("no") before (T0) and after (T28) treatment in the four groups of horses enrolled in the study.

	ESGD		EGGD	
	T0	T28	T0	T28
Group 1 (n = 7)	3	0	Yes	No
	4	2	No	No
	4	1	No	No
	4	0	Yes	No
	2	0	No	No
	2	0	No	No
	4	1	No	No
Group 2 (n = 7)	4	1	No	No
	3	4	Yes	No
	4	0	No	No
	4	2	No	No
	4	3	No	No
	2	4	No	No
	4	0	No	No
Group 3 (n = 8)	3	0	No	No
	2	0	Yes	No
	4	4	Yes	Yes
	4	4	Yes	No
	4	2	No	Yes
	3	0	No	No
	4	4	No	No
	3	NE	Yes	NE
	4	4	No	No
Group 4 (n = 8)	4	3	No	No
	4	4	Yes	No
	4	4	Yes	No
	4	4	Yes	No
	4	4	No	No
	4	4	No	Yes
	4	4	No	No

Abbreviations: EGGD, equine glandular gastric disease; ESGD, equine squamous gastric disease; NE, not evaluated.

#### 2.4. Statistical Analysis

Data on the effect of treatment on EGGD were evaluated with a logistic regression, as they were expressed in binary (yes or no) forms [17]. Logistic regression is a statistical model that in its basic form uses a logistic function to model a binary dependent variable, although many more complex extensions exist. Mathematically, a binary logistic model has a dependent variable with two possible values, such as pass/fail which is represented by an indicator variable, where the two values are labeled "0" and "1."

On the other hand, the ESGD data were assessed for distribution using a Shapiro-Wilk test. Since the data were not normally distributed, the results were expressed as median, minimum, and maximum values. For the same reason, the Mann-Whitney test was used to verify differences between groups at T0 and T28 between treated vs. the corresponding placebo group and between the two omeprazole treated groups.

Significance was determined at  $P < .05$ . Statistical analysis was performed using commercial software (JMP Software, SAS Institute Inc, Cary, NC).

### 3. Results

The gastroscopy was performed in all the horses enrolled at T0 and in 29/30 horses at T28; all the videos recorded were considered acceptable for assessing the gastric lesions. Table 1 shows the results of the ESGD scoring (30/30 at T0 and 29/30 at T28) and the presence/absence of EGGD in all the animals included, while Fig. 1 reports the median score, with minimum and maximum values for ESGD for each group, both at T0 and T28. The response to treatment of ESGD and EGGD in the treated groups was 78.6% and

35.7%, respectively. ESGD was present as various degrees of severity, from small erosions to large ulcers, with similar mean severity all groups at T0. Horses with EGGD presented, at inclusion, various degrees of reddening of the mucosa, without evidence of erosions or ulcers in any part of the glandular lining. After treatment, healed horses showed normal squamous mucosa or only mild hyperkeratosis, with disappearance of the hyperemia in the glandular one, while animals responding only partially, presented small superficial erosions, especially along the lesser curvature. Horses not responding to treatment or administered placebo, showed no changes in the appearance of either glandular or squamous lining.

No adverse effects of either of the omeprazole formulations were observed, nor were signs of systemic diseases diagnosed, thus none of the horses enrolled were excluded during the study period.

No statistically significant differences were found between any of the groups at T0, thus highlighting that the groups were homogeneous in terms of gastric lesions at the beginning of the study.

For ESGD, significant differences ( $P = .002$ ) in lesion scores were found between T0 and T28 in the granular formulation (group 1). Also, the powder paste formulation (group 3), significantly improved lesion score between T0 and T28 ( $P = .01$ ). The two placebo formulations were not significantly different in final lesion scores. Moreover, twenty-eight days of exposure to the placebo formulations did not result in a significant difference of lesion scores (group 2,  $P = .06$  and group 4,  $P = .32$ ).

Clinical signs of gastric ulcers were present in all horses at the beginning of the study, and resolved in all horses treated with omeprazole, while they were still present in the placebo groups.

### 4. Discussion

Our aim was to compare the efficacy of two different gastro-resistant omeprazole formulations in the treatment of ESGD and EGGD in a cohort of adult racehorses. In our study population, both omeprazole formulations allowed for a resolution of lesions in 78.6% of ESGD affected horses and 35.7% of EGGD affected animals. Specifically, in the enteric coated group, 100% of ESGD lesions improved or healed, while in the powder paste group, 71% of animals showed improvement or healing of ESGD, but in this group, 1 animal could not be evaluated after treatment. In the placebo formulation groups, no difference in scores was found between T0 and T28.

Omeprazole is currently the most effective agent for the treatment of gastric ulceration in horses [3,4]. Omeprazole is a substituted benzimidazole which suppresses gastric acid secretion by irreversibly binding to and inhibiting the H<sup>+</sup>/K<sup>+</sup> ATPase enzyme at the luminal secretory surface of the gastric parietal cell [18]. The H<sup>+</sup>/K<sup>+</sup> ATPase or proton-pump is the final step in gastric acid secretion, and once omeprazole is bound it blocks acid secretion regardless of stimuli. The omeprazole powder paste contains omeprazole as an acid-labile, crystalline powder, which is rapidly degraded in the acid environment as it passes through the stomach. For this reason omeprazole requires some form of protection because exposure to gastric acid followed by alkalization in the small intestine makes the drug inactive before absorption can occur [19]. The fraction of the omeprazole that remains intact is absorbed in the small intestine, and then transported via the blood stream to the basal side of the parietal cells where it exerts its effect. Despite acid degradation, the fraction of drug that reaches the small intestine is still effective in healing of gastric ulcers lesions in horses at the recommended dose of 4 mg/kg bwt [13].

The enteric-coated formulations (encapsulated for humans, in paste or in granules for horses) are stable in the acid environment of the stomach, thus protecting the omeprazole from degradation. In the small intestine, the coating is degraded, and the active drug is released [13]. The formulation of omeprazole in gastro-resistant

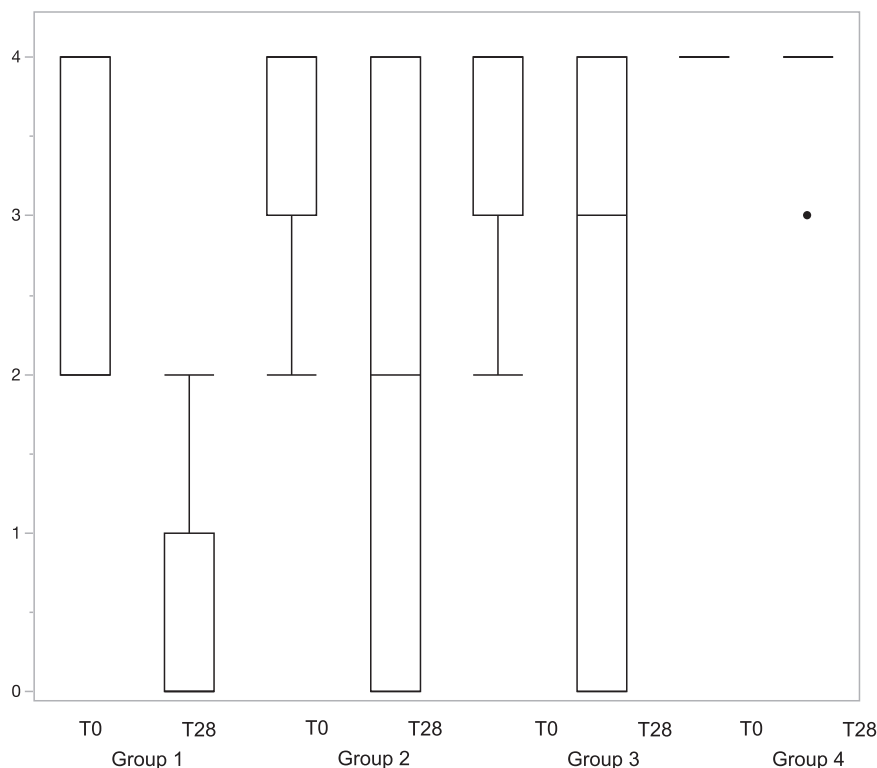


Fig. 1. ESGD scores before (T0) and after treatment (T28) in the 4 groups of treatment. EGGD, equine glandular gastric disease.

granules administered at 4 mg/kg bwt has been reported as being safe and well tolerated by horses [11,20,21]. A few studies have investigated the use of lower doses of gastro-resistant formulations of omeprazole [20–23], mainly considering pharmacokinetic and pharmacodynamic variables. Lower doses were as effective as higher ones for the treatment of ESGD, while response of EGGD was not as satisfactory as ESGD, irrespective of the dose administered [21,22]. Both higher and lower doses were able to achieve good acid suppression when evaluating gastric pH [23,24], but the formulations used in the papers are different, so a comparison of the results is not completely possible. Current recommendations, though, are to administer omeprazole 4 mg/kg bwt, irrespective of the formulation used [3,4].

Overall, in our study both formulations of omeprazole were effective for healing or amelioration of ESGD. The effect on EGGD healing was difficult to evaluate with the current trial design. In fact, glandular mucosa improved also in both placebo groups. In fact, gastric healing was significant after four weeks of treatment compared with admission lesions for ESGD, irrespective of the treatment used. Considering both the prevalence of gastric ulcers in our population and the response to treatment, our results are in line with previous studies [8,19–22,25,26].

For the glandular mucosa, it needs to be considered, that after treatment, most of the affected horses showed normal lining, but some of the healthy ones appeared to have developed lesions even with the treatment. The lower response in horses with EGGD may be related to the duration of the intra-day acid suppression required for healing [10,22,25]. In vitro experiments have demonstrated that protracted exposure of the equine nonglandular gastric mucosa to  $\text{pH} \leq 4.0$  induces functional damage manifested by decreased sodium transport and histologic evidence of cellular swelling [27–30]. In human medicine, studies on gastroesophageal reflux (GERD), which is similar to ESGD, found that good healing rate can be achieved when during a day, the intragastric pH is over 4 for more than 66% of the time. For practical purposes,

a benchmark is set that glandular healing is promoted when intragastric pH is more than 3 for at least 66% of the time [10,31]. The acid-suppression reached after a monotherapy with omeprazole given once a day may be inadequate for healing to occur for EGGD [4,10]. Moreover, the duration of acid suppression achieved with once-daily administration of omeprazole may be as short as 12 hours, even if gastric pH increases above 4 within 1 h of oral administration [19]. Current recommendations state that sucralfate should be used in combination with omeprazole in EGGD [4,32]; in this study, though, because the aim was to evaluate the efficacy of two omeprazole formulations, it was decided not to include a second drug, to avoid risk of confounding factors. Immediately after the end of the study, all EGGD affected horses were further treated with a combination of omeprazole and sucralfate for at least 4 weeks. In the placebo groups, some horses showed healing of the glandular mucosa, even without the administration of the active drug. This could be related to an inherent ability of the gastric lining to repair itself, especially when the lesions are superficial and covered by a mucoid cap [33]. In this population, the horses, despite in active training, did not compete during the study period, and this could reduce the risk of developing gastric ulcers, related to the travel and the stress of the race itself [3,4,6,32].

Comparing the two formulations, our results revealed a similar efficacy of the enteric-coated granules and the powder pasta in the healing of gastric ulcers. Our findings are in line with our previous study [13] which assessed the efficacy of different formulations of omeprazole administered in a single dose of 4 mg/kg. In our previous study, there were no differences in endoscopic findings using the coated granule formulation vs. buffered formulation at a dose of 4 mg/kg PO. The administration of enteric-coated omeprazole at a dose of 4 mg/kg led to a statistical increase in gastric pH, thus highlighting that omeprazole has a dose-dependent effect on gastric acid suppression, which can be enhanced by the enteric coating of the active ingredient [13].



## 5. Conclusions

In conclusion, our study suggests that both formulations of omeprazole used are effective in the treatment of ESGD as already reported by others [13,21,22]. On the other hand, the efficacy of omeprazole alone, in both formulations, for the treatment of EGGD is poor and it may be necessary to supplement treatment with other drugs.

## Authors' contributions

All authors made important contribution to design of the study, collection of the data, drafting of the manuscript. The final version of the manuscript was reviewed and approved by all authors.

## References

- [1] Tamzali Y, Marguet C, Priymenko N, Lyazrhi F. Prevalence of gastric ulcer syndrome in high-level endurance horses. *Equine Vet J* 2011;43:141–4. doi:10.1111/j.2042-3306.2010.00129.x.
- [2] Cate RE, Nielsen BD, Spooner HS, O'Connor-Robison CI, Schott HC. Prevalence of gastric ulcers and relationship to other parameters in Standardbred racehorses. *Comp Exerc Physiol* 2012;8:47–52. doi:10.3920/CEP12009.
- [3] Sykes BW, Hewetson M, Hepburn RJ, Luthersson N, Tamzali Y. European College of Equine internal medicine consensus statement—equine gastric ulcer syndrome in adult horses. *J Vet Intern Med* 2015;29:1288–99. doi:10.1111/JVIM.13578.
- [4] Rendle D, Bowen M, Brazil T, Conwell R, Hallowell G, Hepburn R, et al. Recommendations for the management of equine glandular gastric disease. *UK-Vet Equine* 2018;2:2–11. doi:10.12968/ukve.2018.2.s1.3.
- [5] Sykes BW, Bowen M, Habershon-Butcher JL, Green M, Hallowell GD. Management factors and clinical implications of glandular and squamous gastric disease in horses. *J Vet Intern Med* 2019;33:233–40. doi:10.1111/JVIM.15350.
- [6] Busechian S, Sgorbini M, Orvieto S, Pisello L, Zappulla F, Briganti A, et al. Evaluation of a questionnaire to detect the risk of developing ESGD or EGGD in horses. *Prev Vet Med* 2021;188:105285. doi:10.1016/j.prevetmed.2021.105285.
- [7] Lorenzo-Figueras M, Merritt AM. Effects of exercise on gastric volume and pH in the proximal portion of the stomach of horses. *Am J Vet Res* 2002;63:1481–7. doi:10.2460/ajvr.2002.63.1481.
- [8] Sykes BW, Underwood C, McGowan CM, Mills PC. Pharmacokinetics of intravenous, plain oral and enteric-coated oral omeprazole in the horse. *J Vet Pharmacol Ther* 2015;38:130–6. doi:10.1111/jvp.12169.
- [9] Sykes BW, Underwood C, Greer R, McGowan CM, Mills PC. Pharmacokinetics and bioequivalence testing of five commercial formulations of omeprazole in the horse. *J Vet Pharmacol Ther* 2016;39:78–83. doi:10.1111/jvp.12240.
- [10] Sykes BW, Kathawala K, Song Y, Garg S, Page SW, Underwood C, et al. Preliminary investigations into a novel, long-acting, injectable, intramuscular formulation of omeprazole in the horse. *Equine Vet J* 2017;49:795–801. doi:10.1111/evj.12688.
- [11] Di Salvo A, Busechian S, Zappulla F, Marchesi MC, Pieramati C, Orvieto S, et al. Pharmacokinetics and tolerability of a new formulation of omeprazole in the horse. *J Vet Pharmacol Ther* 2016;40:348–55. doi:10.1111/jvp.12371.
- [12] Gough S, Hallowell G, Rendle D. A study investigating the treatment of equine squamous gastric disease with long-acting injectable or oral omeprazole. *Vet Med Sci* 2020;6:235–41. doi:10.1002/vms3.220.
- [13] Birkmann K, Junge HK, Maischberger E, Wehrli Eser M, Schwarzwald CC. Efficacy of omeprazole powder paste or enteric-coated formulation in healing of gastric ulcers in horses. *J Vet Intern Med* 2014;28:925–33. doi:10.1111/jvim.12341.
- [14] Henneke DR, Potter GD, Kreider JL, Yeates BF. Relationship between condition score, physical measurements and body fat percentage in mares. *Equine Vet J* 1983;15:371–2. doi:10.1111/j.2042-3306.1983.tb01826.x.
- [15] Sykes BW, Jokisalo JM. Rethinking equine gastric ulcer syndrome: Part 1 – terminology, clinical signs and diagnosis. *Equine Vet Educ* 2014;26:543–7. doi:10.1111/EVE.12236.
- [16] Bain FT, Petrizzi L, Valbonetti L, Muttini A. Gastroscopy and duodenoscopy. *Atlas Equine Endosc*; 2004. p. 147–68. doi:10.1016/B978-0-323-01848-7.50012-9.
- [17] Tolles J, Meurer WJ. Logistic regression relating patient characteristics to outcomes JAMA guide to statistics and methods. *JAMA* 2016;2:533.
- [18] Lorentzon P, Eklundh B, Brändström A, Wallmark B. The mechanism for inhibition of gastric (H+ + K+)-ATPase by omeprazole. *BBA - Biomembr* 1985;817:25–32. doi:10.1016/0005-2736(85)90064-1.
- [19] Merritt AM, Sanchez LC, Burrow JA, Church M, Ludzia S. Effect of GastroGard and three compounded oral omeprazole preparations on 24 h intragastric pH in gastrically cannulated mature horses. *Equine Vet J* 2003;35:691–5. doi:10.2746/042516403775696339.
- [20] Wise JC, Hughes KJ, Edwards S, Jacobson GA, Narkowicz CK, Raidal SL. Pharmacokinetic and pharmacodynamic effects of 2 registered omeprazole preparations and varying dose rates in horses. *J Vet Intern Med* 2021;35:620–31. doi:10.1111/jvim.15971.
- [21] Sykes BW, Sykes KM, Hallowell GD. A comparison of two doses of omeprazole in the treatment of equine gastric ulcer syndrome: a blinded, randomised, clinical trial. *Equine Vet J* 2014;46:416–21. doi:10.1111/evj.12191.
- [22] Sykes BW, Sykes KM, Hallowell GD. A comparison of three doses of omeprazole in the treatment of equine gastric ulcer syndrome: a blinded, randomised, dose-response clinical trial. *Equine Vet J* 2015;47:285–90. doi:10.1111/evj.12287.
- [23] Huxford KE, Dart AJ, Perkins NR, Bell R, Jeffcott LB. A pilot study comparing the effect of orally administered esomeprazole and omeprazole on gastric fluid pH in horses. *N Z Vet J* 2017;65:318–21. doi:10.1080/00480169.2017.1359125.
- [24] Sykes BW, Underwood C, Greer R, McGowan CM, Mills PC. The effects of dose and diet on the pharmacodynamics of omeprazole in the horse. *Equine Vet J* 2017;49:525–31. doi:10.1111/evj.12630.
- [25] Sykes BW, Sykes K, Hallowell GD. Comparison of the effect of two doses of omeprazole on the squamous gastric mucosa in thoroughbred racehorses. *Vet Rec* 2014;175:249. doi:10.1136/vr.102622.
- [26] Sykes BW, Sykes KM, Hallowell GD. A comparison between pre- and post exercise administration of omeprazole in the treatment of equine gastric ulcer syndrome: A blinded, randomised, clinical trial. *Equine Vet J* 2014;46:422–6. doi:10.1111/evj.12083.
- [27] Widenhouse TV, Lester GD, Merritt AM. Effect of hydrochloric acid, pepsin, or taurocholate on bioelectric properties of gastric squamous mucosa in horses. *Am J Vet Res* 2002;63:744–9. doi:10.2460/ajvr.2002.63.744.
- [28] Nadeau JA, Andrews FM, Patton CS, Argenzio RA, Mathew AG, Saxton AM. Effects of hydrochloric, valeric and other volatile fatty acids on pathogenesis of ulcers in the nonglandular portion of the stomach of horses. *Am J Vet Res* 2003;64:413–17. doi:10.2460/ajvr.2003.64.413.
- [29] Nadeau JA, Andrews FM, Patton CS, Argenzio RA, Mathew AG, Saxton AM. Effects of hydrochloric, acetic, butyric, and propionic acids on pathogenesis of ulcers in the nonglandular portion of the stomach of horses. *Am J Vet Res* 2003;64:404–12. doi:10.2460/ajvr.2003.64.404.
- [30] Andrews FM, Buchanan BR, Smith SH, Elliott SB, Saxton AM. In vitro effects of hydrochloric acid and various concentrations of acetic, propionic, butyric, or valeric acids on bioelectric properties of equine gastric squamous mucosa. *Am J Vet Res* 2006;67:1873–82. doi:10.2460/ajvr.67.11.1873.
- [31] Bell NJV, Burget D, Howden CW, Wilkinson J, Hunt RH. Appropriate acid suppression for the management of gastro-oesophageal reflux disease. *Digestion* 1992;51:59–67. doi:10.1159/000200917.
- [32] van den Boom R. Equine gastric ulcer syndrome in adult horses. *Vet J* 2022(283-284):105830. doi:10.1016/j.tvjl.2022.105830.
- [33] Sanchez LC. Disorders of the gastrointestinal system. In: *Equine Internal Medicine*. Elsevier Inc.; 2018. p. 709–842. doi:10.1016/B978-0-323-44329-6.00012-7.