

Case Report

NEUROENDOCRINE BREAST TUMOUR: A CHALLENGING ENTITY

TUMOR NEUROENDOCRINO DE MAMA: UNA ENTIDAD DESAFIANTE

Sara Palomares-Casasús^{*1}; Marcos Rolando Adrianzén¹, Maria Luisa Spa¹, Octavio Burgués¹, Juan Miguel Cejalvo¹, Elvira Buch¹, Gemma Bellver Lobato¹

¹ Department of General Surgery, University Clinical Hospital of Valencia. Avenida Blasco Ibáñez 17. Valencia. Spain.

*Corresponding Author:

Sara Palomares-Casasús

Department of General Surgery, University Clinical Hospital of Valencia. Avenida Blasco Ibáñez 17. Valencia. Spain.

E-mail: sara.palomares@hotmail.com

Received: 02 October 2021, Approved: 09 December 2021, Published: February 2022

Abstract

Neuroendocrine breast carcinoma is a rare type of breast cancer with neuroendocrine differentiation, which is found in around 2-5% of all invasive breast carcinomas. In most cases it is a challenge to get to the right diagnosis due to the sporadic number of cases and the need for special immunochemistry techniques, which are not routinely used. Due to the rare number of cases, it is difficult to update guidelines so that the correct diagnosis and treatment is decided. Our purpose is to present a clinical case in order to emphasize the importance of having this diagnosis in mind when breast cancer is found.

Resumen

El carcinoma neuroendocrino de mama es un tipo de cáncer poco frecuente que presenta diferenciación neuroendocrina y que se encuentra entre el 2-5% de todos los carcinomas invasivos de mama. En la mayoría de los casos, llegar al diagnóstico correcto es un reto dado el esporádico número de casos y la necesidad de utilizar técnicas inmunohistoquímicas especiales que no se encuentran de rutina. Dado el escaso número de casos, es difícil actualizar las guías clínicas que permitan llegar al diagnóstico y tratamiento correcto. Nuestro objetivo es presentar un caso clínico con la intención de destacar la importancia de tener este subtipo oncológico entre el diagnóstico diferencial en el cáncer de mama.

Keywords: Adrenal Gland, Pseudoaneurysm, Haemorrhage, Embolization.

Introduction

Neuroendocrine breast carcinoma (NEBC), which was first described in 1963 by Feyrter and Hartmann, is a rare entity usually found between the sixth and seventh decade of female patients ^(1,4). It is a rare type of breast cancer with neuroendocrine differentiation which is found in around 2-5% of all invasive breast carcinomas ^(1,5). The incidence of this type of cancer is not well established due to the sporadic number of cases and the lack of uniformity in diagnostic criteria, running between 0,1-18% ^(1,2).

Neither the treatment, nor the prognosis are really well known. In order to establish the diagnosis, histopathological and special immunohistochemical exams are required, which indeed are not currently the standard tests used for the diagnosis of breast cancer ⁽⁵⁾.

We present a sonographic, mammographic, CT-scan and magnetic resonance imaging findings of a primary neuroendocrine breast cancer in a 45-year-old woman.

Case Report

We present a 45-year-old woman, with early-detected family history of breast cancer, who referred thoracic thrombophlebitis and mammalian asymmetry of months of evolution. Gigantomastia was found during the physical examination (Figure 1). Breast asymmetry was evident with increased right breast volume. Skin thickening and cutaneous inflammatory signs could be also described. No other anomalies were found.

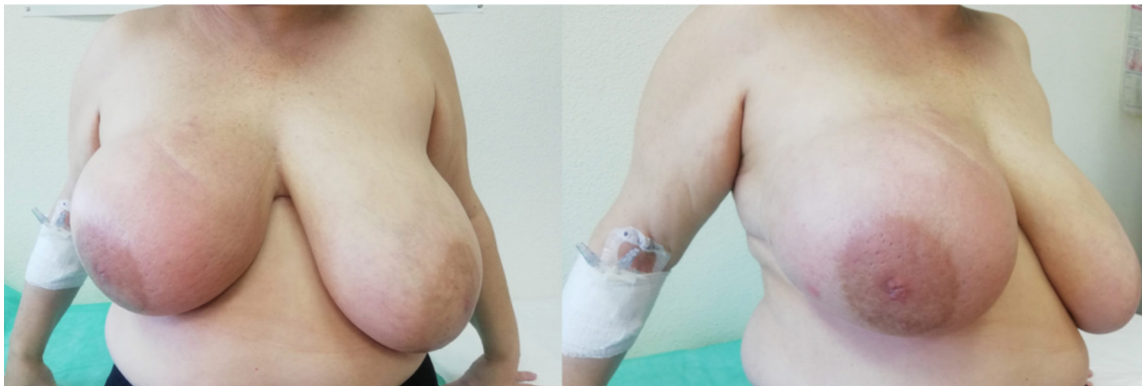

Figure 1. Physical examination revealed breast asymmetry with edematous cutaneous signs”.

Due to the clinical signs, the patient was asked for radiological complementary tests (figure 2). The breast ultrasound (figure 2a) revealed extensive cutaneous inflammatory signs and diffuse edema, most relevant in the upper quadrants. In the external quadrants, a hypoechoic area not well defined was found. In the axillary region a pathological round adenopathy without fat hilum was identified.

The study was completed with bilateral breast mammography (figure 2b) which showed an area with poorly defined borders with spiculated edges in the upper-external quadrant of the right breast. An increase in retroareolar density and in the thickness of the right breast skin was also found with benign bilateral scattered microcalcifications.

A breast magnetic resonance (figure 2c and 2d) was also carried out which concluded; multicentric, locally advanced breast cancer with affected ipsilateral axilla. Skin thickening was also observed. Dynamic imaging revealed contrast recruitment in tumoral area.

The right breast lesion was biopsied and an infiltrative breast carcinoma with neuroendocrine differentiation and negativity for hormone receptors and HER2 and Ki67 of 80% and extensive linfo-vascular infiltration was described after anatomopathological examination. The suspicious ipsilateral adenopathy was also positive for carcinoma.

To assure the neuroendocrine differentiation during anatomopathological examination, several immunohistochemistry's techniques were required. The most common dyes are hematoxilin-eosin (figure 3a) and GATA3, which positivity is related to mammary tissue (figure 3b). Other typical ones are chromogranin and synaptophysin dyes, which are characteristically positive in this kind of tumor (figure 3c and 3d). Other dyes that can be used are thyroid transcription factor-1 (TTF-1) and estrogen receptors (figure 3e and 3f).

The thoraco-abdominal-pelvic CT was requested in order to establish the extension of the illness and the findings were a hepatic lesion in the IV segment and osteolytic bone lesions in L3 vertebra, which were both suggestive of breast metastasis. In the right breast several pseudonodular lesions were detected associated to severe cutaneous thickening in relation to the multifocal neoplasia already diagnosed (figure 2e-h). Diffuse right pectoral thickening was also described.

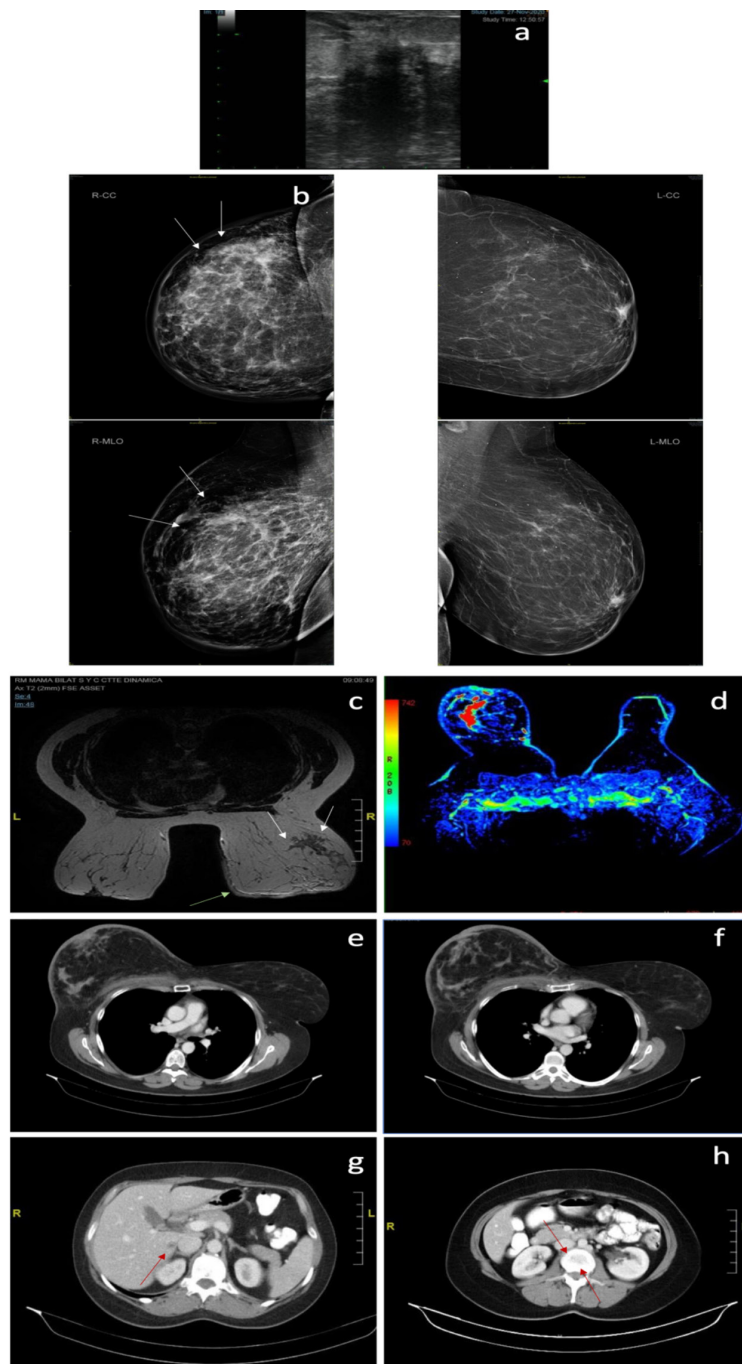


Figure 2. Radiological tests.

A) Breast ultrasound showed a hypoechoic area not well defined in external quadrant of right breast.

B) Bilateral mammography showed a poorly defined area with spiculated edges in the upper-external quadrant of the right breast (white arrows) and an increase in retroareolar density and in the thickness of the right breast skin with benign bilateral scattered microcalcifications.

C) Magnetic resonance revealed a locally advanced multicentric right breast neoplasms that predominantly affects super-external quadrants, upper inter quadrant line and infero-external quadrant (white arrows). Skin thickening on the anterior and medial right breast face (green arrow).

D) Dynamic resonance imaging with the contrast recruitment (red-coloured) in tumor's region.

E-F) Severe cutaneous and right pectoral thickening with several pseudonodular lesions associated.

G) Hypodense focal lesion in medial region of the IV hepatic segment (red arrow).

H) Little osteolytic bone lesions in L3 vertebral body (red arrows).

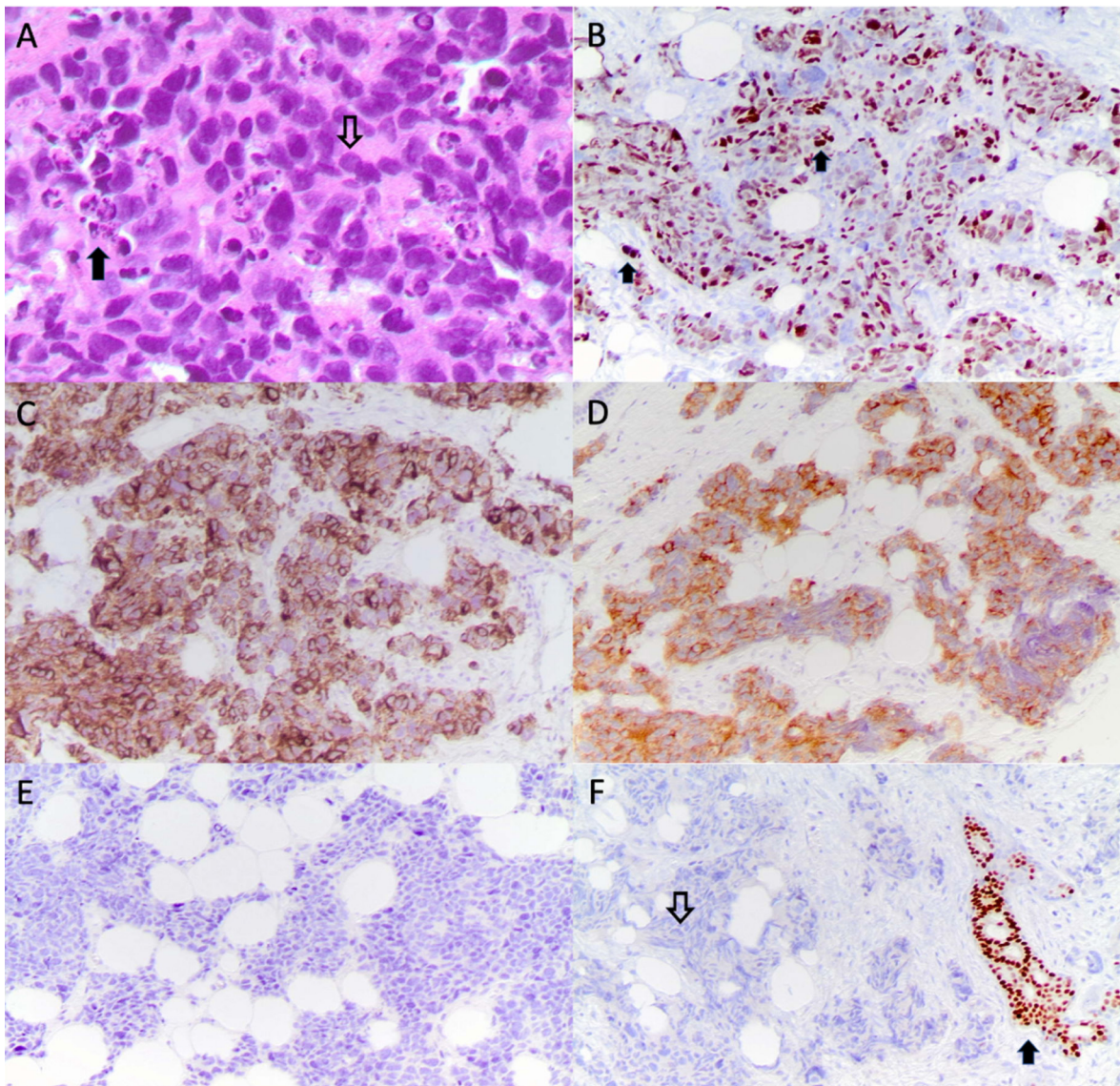


Figure 3.

A) Hematoxylin-eosin (40x): The nuclei are hyperchromatic and have poorly defined cytoplasm, with overlapping nuclei (▼). Numerous apoptotic bodies are typically observed (▲), which is a sign of intense divisional activity and necrosis.

B) GATA3 (20x): Generalized nuclear expression of GATA3 is observed, suggesting mammary origin.

C-D) Chromogranin/synaptophysin (10x): Immunohistochemical stains reveal widespread positivity for Chromogranin (c) and Synaptophysin (d), which are neuroendocrine tumor markers.

E) TTF1 (10x): Nuclei show absent expression of TTF-1.

F) ER (10x): the immunohistochemical analysis shows negative expression of the estrogen receptor (▲). A normal positive duct can be seen and serves as an internal control (▼).

Due to the clinical situation where the primary tumor stands out but there seems to be metastatic illness, the decision was to start with chemotherapy in order to reduce the size, followed by surgery and radiotherapy.

Discussion

Although NEBC are a rare entity, it is important to have them in mind in the differential diagnosis of breast cancer due to their inherent worse prognosis and therapeutic limitations, especially after excluding other primary neuroendocrine tumors.

Arriving to the correct diagnosis of NEBC can be a real challenge. Signs and symptoms are comparable to other types of breast cancers and these tumors are exceptionally associated to functional syndromes⁽³⁾. Imaging findings are not specific, being usually described in mammography as circumscribed lesions without surrounding microcalcifications and as irregular, hypoechogenic lesions when using ultrasonography⁽¹⁾. For that reason, histopathological and immunohistochemistry examinations are necessary to get to the definitive diagnosis⁽²⁾. As any other tumors, it can metastasize, being bones and liver the most frequent localizations⁽¹⁾.

In 2003, the World Health Organization (WHO) established three criteria for the NEBC⁽³⁾:

1- More of 50% of breast neoplastic cells positive for neuroendocrine markers such as chromogranin A, synaptophysin or neuron specific enolase.

2- Exclude other primary extra-mammary tumors, such as lung or gastroenteric tract.

3- Concomitant component in situ in the breast

In 2012, the WHO included all carcinomas with neuroendocrine differentiation independently of the percentage of cells expressing neuroendocrine markers, so they were subdivided into three groups: well-differentiated, poorly differentiated or small cells carcinomas and carcinomas with neuroendocrine differentiation⁽²⁾.

In a recent revision undertaken in 2019, new criteria were established, so that a NEBC are defined as invasive carcinomas with low or intermediate grade neuroendocrine morphology with neurosecretory granules and positivity for neuroendocrine markers⁽³⁾.

Other histopathological findings are⁽³⁾:

- Positivity for estrogen receptors
- Low Ki67 index
- Negativity for HER2 overexpression

It is important to exclude other primary neuroendocrine tumors that could have metastasized in the breast, such as lung or gastrointestinal cancers, performing a complete CT-scan or even a somatostatin receptor scintigraphy in case of well-differentiated tumors or a positron emission tomography when finding a poorly differentiated neoplasm^(1,3). Other diagnosis to have in mind are Merkel cell carcinoma, lymphoma or melanoma⁽⁵⁾.

In fact, around two-thirds of all NEBC were initially typified as infiltrative ductal breast cancer and were rectified after analyzing the surgical specimen, so surgery is important for the definitive diagnosis⁽⁵⁾.

Prognostic factors are similar to other invasive breast cancers such as age, axillary lymph nodes affection, hormone receptors, Ki67 index or intratumoral lymphocytes percentage⁽³⁾. Historically it was thought to have similar prognosis to other breast types cancer, but recent studies report aggressive course with worse long-term outcomes⁽¹⁾.

There are no specific guidelines for NEBC, so indications for treatment are similar to the other type of invasive breast cancer. Multidisciplinary treatment is usually required, which combines surgery with chemo and radiotherapy. The location of the tumor and the clinical stage will focus on the best surgical procedure⁽⁵⁾. As they tend to be related to luminal phenotype, endocrine therapy could be useful in some cases as well as anti-HER2 treatment, when it is overexpressed⁽¹⁾. When suspected axillary nodes, macrometastasis affected sentinel nodes, impossibility to find sentinel lymph node, or in T4 tumors or inflammatory carcinomas, axillary dissection removing more than 10 lymph nodes is required⁽³⁾. Some studies affirm that NEBC seem to be chemoresistant so individual indications should be considered⁽⁶⁾.

Conclusion

NEBC should be part of the differential diagnosis of breast cancer, especially after excluding other primary neuroendocrine tumors, and it is important to have in mind their worse prognosis and therapeutic limitations. Due to the rare number of known cases and the specific techniques needed to get to the diagnosis, no updated guidelines can be followed, so further studies are necessary in order to establish the best course of treatment. Surgery is the mainstay

of the treatment for early NECB, and the surgical procedure will depend on the location of the tumor and on the clinical stage. The adjuvant/neoadjuvant therapy in NEBC, it should be prudentially considered according to the same indications adopted for the other types of invasive breast cancer and the decision should be made individualized in a multidisciplinary committee. On the other hand, there are no NEBC-specific treatments in the metastatic setting. For the moment, the therapeutic approach for this kind of patients should be individualized and the treatment strategy should be based on the characteristics of the tumor, the age, menopausal status, general conditions and preferences of the patient. In our case, it was decided neoadjuvant therapy and, depending on the response to treatment, the surgical approach would be considered.

Author's statements

- Ethical Approval: The Patient signed the informed consent. Approval received by ethical committee and patient identity information is not shared in this article.
- Conflicts of Interest: The authors declare the non-existence of conflicts of interest.

References

1. Trevisi, Elena, et al. “Neuroendocrine Breast Carcinoma: a Rare but Challenging Entity.” *Medical Oncology*, vol. 37, no. 8, 2020, doi:10.1007/s12032-020-01396-4.
2. Valentim, Maria Helena, et al. “Primary Neuroendocrine Breast Carcinoma: a Case Report and Literature Review.” *Radiologia Brasileira*, vol. 47, no. 2, 2014, pp. 125–127., doi:10.1590/s0100-39842014000200017.
3. Irelli, Azzurra, et al. “Neuroendocrine Cancer of the Breast: A Rare Entity.” *Journal of Clinical Medicine*, vol. 9, no. 5, 2020, p. 1452., doi:10.3390/jcm9051452.
4. Puente Blanco, Rebeca, et al. “Cáncer Neuroendocrino De Mama. A Propósito De Un Caso.” *Revista De Senología y Patología Mamaria*, vol. 28, no. 3, 2015, pp. 143–144., doi:10.1016/j.senol.2015.04.003.
5. Tsai, Tsung-Hsien, et al. “Metastatic Primary Neuroendocrine Carcinoma of the Breast (NECB).” *Journal of Cancer Research and Practice*, vol. 5, no. 1, 2018, pp. 38–42., doi:10.1016/j.jcrpr.2017.10.003.
6. Rosen, Lauren Elizabeth, and Paolo Gattuso. “Neuroendocrine Tumors of the Breast.” *Archives of Pathology & Laboratory Medicine*, vol. 141, no. 11, 2017, pp. 1577–1581., doi:10.5858/arpa.2016-0364-rs.