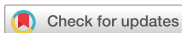

Original Article
Anesthesiology



Description of a novel ultrasound guided peribulbar block in horses: a cadaveric study

Hannah Leigh ^{1*}, Miguel Gozalo-Marcilla ¹, Vicente Esteve ²,
Álvaro Jesús Gutiérrez Bautista ³, Tamara Martin Gimenez ²,
Jaime Viscasillas ²

¹The Royal (Dick) School of Veterinary Studies and The Roslin Institute, Easter Bush Campus, The University of Edinburgh, Bush Farm, Roslin. EH25 9RG, Scotland, UK

²Departamento de Medicina y Cirugía Animal, Facultad de Veterinaria, Universidad Cardenal Herrera-CEU, CEU Universities, Valencia 46115, Spain

³Clinic for Small Animals, University of Veterinary Medicine, Hannover 305559, Germany

 OPEN ACCESS

Received: Nov 13, 2020

Revised: Jan 23, 2021

Accepted: Jan 26, 2021

*Corresponding author:


Hannah Leigh

The Royal (Dick) School of Veterinary Studies and The Roslin Institute, Easter Bush Campus, The University of Edinburgh, Bush Farm, Roslin, EH25 9RG, Scotland, UK.
E-mail: Hannah.leigh@ed.ac.uk

© 2021 The Korean Society of Veterinary Science

This is an Open Access article distributed under the terms of the Creative Commons Attribution Non-Commercial License (<https://creativecommons.org/licenses/by-nc/4.0>) which permits unrestricted non-commercial use, distribution, and reproduction in any medium, provided the original work is properly cited.

ORCID iDs

Hannah Leigh 


<https://orcid.org/0000-0001-7110-047X>

Miguel Gozalo-Marcilla 

<https://orcid.org/0000-0003-1391-0989>

Vicente Esteve 


<https://orcid.org/0000-0002-0724-0547>

Álvaro Jesús Gutiérrez Bautista 

<https://orcid.org/0000-0002-0415-4475>

Tamara Martin Gimenez 

<https://orcid.org/0000-0003-4558-0048>

Jaime Viscasillas 

<https://orcid.org/0000-0003-0162-941X>

Conflict of Interest

The authors declare no conflicts of interest.

ABSTRACT

Background: Standing surgery in horses combining intravenous sedatives, analgesics and local anaesthesia is becoming more popular. Ultrasound guided (USG) peribulbar nerve block (PB) has been described in dogs and humans for facial and ocular surgery, reducing the risk of complications *versus* retrobulbar nerve block (RB).

Objective: To describe a technique for USG PB in horse cadavers.

Methods: Landmarks and PB technique were described in two equine cadaver heads (*Phase 1*), with computed tomography (CT) imaging confirming contrast location and spread. In *Phase 2*, ten equine cadaver heads were randomised to two operators naïve to the USG PB, with moderate experience with ultrasonography and conventional “blind” RB. Both techniques were demonstrated once. Subsequently, operators performed five USG PB and five RB each, unassisted. Contrast location and spread were evaluated by CT. Injection site success was defined for USG PB as extraconal contrast, and for RB intraconal contrast.

Results: Success was 10/10 for USG PB and 0/10 for RB ($p < 0.001$). Of the RB injections, eight resulted in extraconal contrast and two in the masseter muscle ($p = 0.47$).

Conclusions: The USG PB had a high injection site success rate compared with the RB technique; however, we cannot comment on clinical effect. The USG technique was easily learnt, and no potential complications were seen. The USG PB nerve block could have a wide application for use in horses for ocular surgeries (enucleations, eyelid, corneal, cataract surgeries, and ocular analgesia) due to reduced risk of iatrogenic damage. Further clinical studies are needed.

Keywords: Local anaesthesia; nerve; ocular; surgery

INTRODUCTION

In equine practice, the mortality rate for healthy horses undergoing general anaesthesia remains approximately 0.9% [1]. The risks of general anaesthesia can be avoided by performing surgery in the standing horse with combinations of intravenous sedatives, analgesics [2,3] and local anaesthetic techniques. For standing enucleations, a retrobulbar nerve block (RB) is routinely used to provide analgesia and akinesia, the loss of voluntary

Author Contributions

Conceptualisation: Viscasillas J; Data curation: Leigh H, Gozalo-Marcilla M, Esteve V, Gutierrez A, Martin T, Viscasillas J; Formal analysis: Leigh H, Esteve V, Viscasillas J; Investigation: Leigh H, Gutierrez A, Martin T, Viscasillas J; Methodology: Leigh H, Gozalo-Marcilla M, Esteve V, Gutierrez A, Martin T, Viscasillas J; Project administration: Gozalo-Marcilla M; Resources: Viscasillas J; Software: Esteve V; Supervision: Gozalo-Marcilla M, Viscasillas J; Writing - original draft: Leigh H; Writing - review & editing: Leigh H, Gozalo-Marcilla M, Gutierrez A, Martin T, Esteve V, Viscasillas J.

eye movement [4]. The use of a “blind” technique to perform a RB for procedures other than enucleation is controversial due to the potential risk of iatrogenic damage to the globe, retrobulbar haemorrhage and nerve penetration.

Motor and sensory innervation of the equine eye and eyelids is supplied by the auriculopalpebral, oculomotor, abducens, trochlear and ophthalmic nerves (or cranial nerves VII, III, VI, IV, V), which all (with the exception of the auriculopalpebral nerve) pass through the orbital fissure at the back of the orbit [5,6]. The maxillary nerve (which supplies innervation to the lower eyelid) is in close proximity to the orbital fissure in the horse as it exits the alar canal [5]; therefore administration of local anaesthetic to the level of the orbital fissure results in widespread desensitisation of the eye, eyelids and periocular area.

Peribulbar nerve block (PB) has been described in dog cadavers [7-9], live dogs [10,11] and cats [12] but not in horses. With this technique, the local anaesthetic is deposited outside of the extraocular muscle cone, avoiding key structures such as the optic nerve and ophthalmic blood vessels. Due to the peribulbar compartment being a potential space between the extraocular muscle cone and surrounding temporalis muscle, an injection here allows injectate to track between fascial planes to the orbital foramen, as shown in canine cadavers [9]. This approach may have advantages over the RB technique due to a theoretical lower complication rate [13-15], and as a consequence a wider application for use.

The use of ultrasonography to guide local anaesthetic techniques is becoming established in small animal anaesthesia [16], and several ultrasound guided (USG) techniques are now described in horses for various procedures [17-19]. Human evidence shows improved blockade and reduced complication rates such as vascular puncture when an USG technique is used [20]. An USG RB nerve block has been described in equine cadavers [21] but has yet to be evaluated clinically.

The primary aim of this study was to describe a novel method for USG PB in equine head cadavers, using computed tomography (CT) imaging to confirm correct location of contrast medium (*Phase 1*). The secondary aims were to compare success rates of both USG PB and “blind” RB with two naïve operators, and to assess spread of contrast medium for each technique (*Phase 2*). We hypothesise that the USG technique will have a higher injection site success rate than the RB technique.

MATERIALS AND METHODS

The study was performed on equine cadaver heads of horses euthanised for reasons unrelated to this study. The European Union directive and the Royal Decree on the protection of animals for scientific purposes and teaching (2010/63/UE, RD 53/2013) were adhered to.

Phase 1 - nerve block description

Two thawed equine cadaver heads were used for description of the technique (one Thoroughbred, one Warmblood). Hair was removed bilaterally around the area of the supraorbital fossa and the area cleaned with alcohol before applying ultrasound (US) gel. The globe was injected with US gel to restore globe size, increase intraocular pressure and optimise sonoanatomy of the cadaver heads. Similar techniques using saline have been described elsewhere [21,22]. A 5-1 MHz Phased US probe was placed over the supraorbital

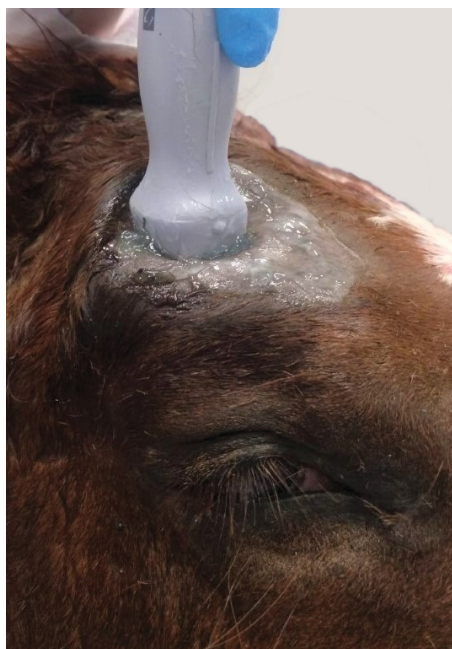


Fig. 1. Placement and orientation of the US probe on the supraorbital fossa.

fossa perpendicular to the orbital rim (**Fig. 1**). A 19-gauge 3.5-inch spinal needle was primed with saline and a 2.5 mL syringe of saline attached.

The needle was inserted alongside the US probe in the supraorbital fossa using an in-plane technique, approximately 2 cm behind the probe in a caudal-cranial direction (**Fig. 2**). It was then advanced until the tip was adjacent to but not inside the extraocular muscle cone. At this

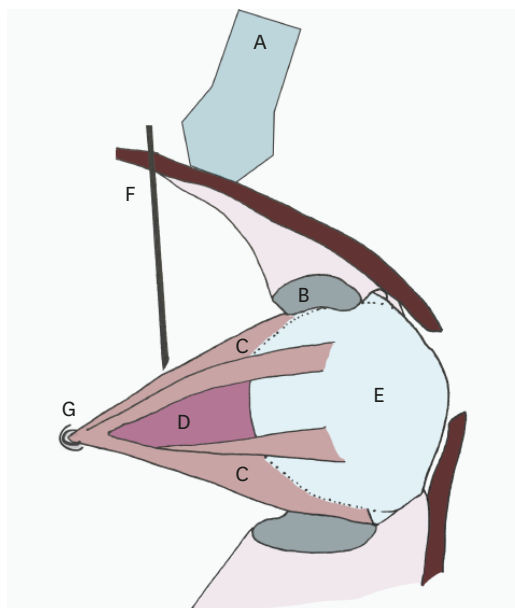


Fig. 2. Illustration of the lateral view of the equine orbit, with needle adjacent to the myofascial extraocular muscle cone.
A, US probe; B, orbital rim; C, myofascial extraocular muscle cone; D, retrobulbar space/intraconal compartment; E, globe; F, needle; G, orbital fissure.

point 1 mL of saline was injected to confirm correct needle placement, which was defined as ventral movement of the border of the extraocular muscle cone upon injection. Once this was confirmed, 10 mL of 50% saline 50% iodinated contrast (Iohexol [Omnipaque 300 mg-I/mL], GE Healthcare, Spain) mixture was injected. The opposite eye was scanned in the same manner; however, this time the needle was purposely advanced inside the extraocular muscle cone and 10 mL of the saline-contrast mixture injected. Location and spread of injectate were confirmed using CT imaging with both techniques.

Phase 2 - technique comparison

Subsequently, ten equine cadaver heads of a range of breeds were randomised to two naïve operators who had not been present during *Phase 1* and who had no prior experience with the USG PB technique. Both were veterinarians: one, a junior anaesthetist (OpA) and the other, an equine surgery resident (OpS). The operators had had some experience using ultrasonography, and moderate experience with the “blind” RB technique.

Both techniques were demonstrated to the operators once: firstly, the USG PB technique, and secondly, the “blind” RB technique using a well-known, previously described method [6]. In short, the needle was placed caudal to the dorsal orbital rim over the supraorbital fossa and slowly advanced. Once the needle reached the extraocular muscle cone, the eye had a slight dorsal movement as the needle pushed against the fascia and fell to a central position once the needle penetrated the extraocular muscle cone, accompanied by a “popping” sensation [6]. Following demonstration of the techniques, each operator performed both on each of the 5 equine heads assigned to them. The heads were first prepared as per *Phase 1*. The heads, technique (RB or PB) and orbit (left or right) were randomised and assigned. No assistance was given to the operators with regard to technique.

Once all injections had been completed, the heads underwent CT imaging to assess location and spread of injectate. Injection site success was defined differently in each group: in the USG PB group as extraconal contrast (in the peribulbar space), and in the RB group as the presence of intraconal contrast. The spread of contrast to the orbital fissure, rostral alar foramen, oval foramen, mandibular nerve and skull was also recorded. All CT images were interpreted and reported by a single radiologist undergoing specialist residency training who was unaware as to which technique had been used.

All statistical tests were performed using commercially available software (Minitab 17 Statistical Software 2010; Minitab, LLC, USA). Differences in success rates between techniques and operators were checked for, using Fisher's exact tests. Values of $p < 0.05$ were deemed statistically significant in all cases.

RESULTS

Phase 1: orientation of the US probe as depicted in **Fig. 1** allowed imaging of the retrobulbar region. The US image showed the orbital rim with acoustic shadowing cranially, and the myofascial extraocular muscle cone visible as a well-defined cone shape caudal to this shadowing (**Fig. 3, Supplementary Video 1**). Injection of contrast-saline mixture just outside of the myofascial extraocular muscle cone resulted in contrast spread within the peribulbar space, seen on CT imaging. When the needle was purposely advanced into the extraocular muscle cone under US guidance, CT images confirmed contrast within the retrobulbar space.

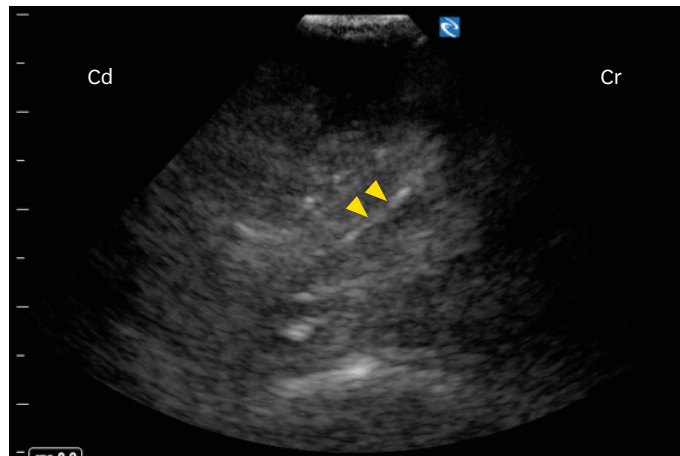


Fig. 3. US image achieved with placement of the US probe as depicted in **Fig. 1**. Yellow arrow heads, border of the myofascial extraocular muscle cone; Cr, cranial; Cd, caudal.

Phase 2: within this phase, a total of twenty injections were performed, ten by each naïve operator, and ten of each technique. In two cases (2/10 USG PB), the operators described difficulty in identifying the ultrasound landmarks. Despite this, 10/10 USG PB nerve blocks were successfully injected in their intended location compared to none in the RB group ($p < 0.001$). Two injections of the twenty resulted in injection of contrast into the masseter muscle (**Fig. 4**). Both were in the RB group; however, this difference between techniques was not statistically different ($p = 0.473$). No significant difference was found between operators as regards injection site success rate (OpA 5/10 vs. OpS 5/10, $p > 0.99$) or number of IM injections (OpA 0/10 vs. OpS 2/10, $p = 0.473$). Contrast spread to the orbital fissure (**Fig. 5**) was seen with six injections (6/18, discounting 2 IM injections): 4 in the RB group, 2 in USG PB group, all within the peribulbar space. However, this difference was not significantly different between groups ($p = 0.629$). No contrast was seen at the other deeper locations

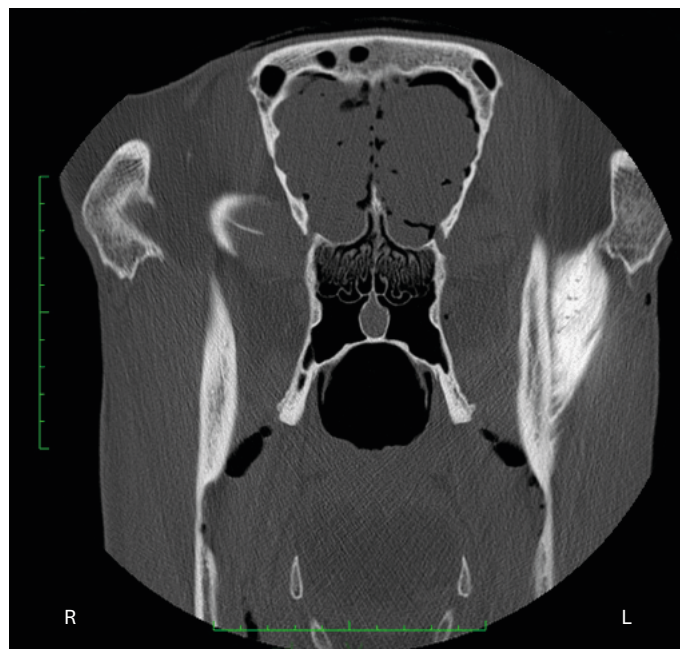


Fig. 4. Computed tomography image showing IM contrast, following unsuccessful retrobulbar injection.

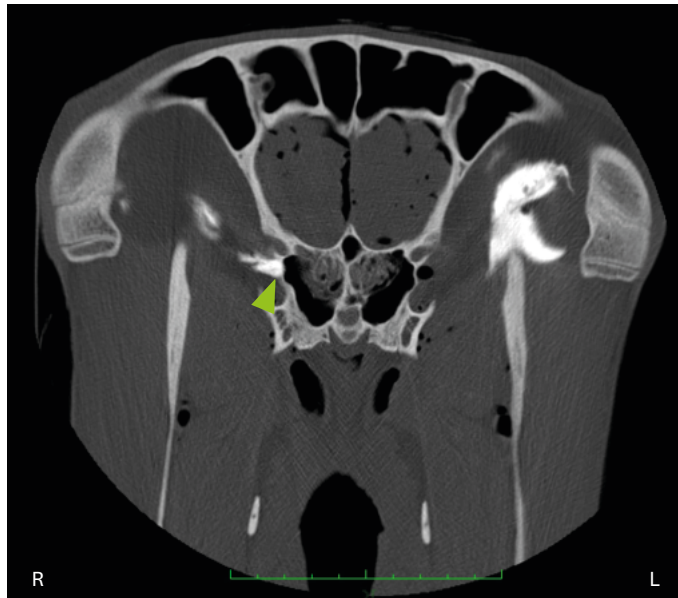


Fig. 5. Computed tomography image showing a transverse view of both orbits and bilateral presence of contrast in the peribulbar space. Contrast can be seen at the level of the R orbital fissure (green arrowhead).

monitored (rostral alar foramen, oval foramen, mandibular nerve and skull). No evidence of globe penetration or intraneural injection was seen with any technique.

DISCUSSION

This is the first study where USG PB has been described and demonstrated successfully in horses. The approach described in *Phase 1* is an easy way to perform the USG PB with excellent injection site success demonstrated in *Phase 2* in the hands of naïve operators. In contrast, none of the “blind” RB injections were in the retrobulbar space, with the majority (8/10) in fact in the peribulbar space. This highlights the advantages of ultrasound guidance, to enable needle visualisation and injection of local anaesthetic in the intended location with confidence. It also concurrently allows identification and avoidance of key structures, therefore reducing the risk of inadvertent intravascular injection, globe penetration, haematoma and intraneural injection.

In *Phase 1* we described a novel technique to perform an USG PB in horses. Injection of local anaesthetic in the peribulbar space can result in blockade of the oculomotor, abducens, trochlear and ophthalmic nerves as they pass through the orbital fissure [5,23,24], desensitising the eye and periorbital region. Furthermore, local anaesthetic has been shown to migrate into the intraconal space from the peribulbar space in other species [12,25], resulting in a complete blockade of the eye and its adnexa.

A similar USG PB technique in dog cadavers reported maxillary nerve staining [8] and a clinical study in cats showed the PB providing corneal and periorbital analgesia [12]. The use of PB providing analgesia and a central eye for cataract surgery is reported in dogs [10] and is used routinely in humans [14]. In horses it could be an alternative to systemic neuromuscular blocking agents for achieving a central eye under general anaesthesia for ocular surgery, eliminating the risks associated with their use and antagonism [26]. A clinical study assessing the area of sensory and motor blockade with a single PB injection in live horses is required for confirmation.

This study is the first describing an USG PB in horses. A technique for USG RB has been described by Morath et al. [21] but uses a different approach. An “out of plane” technique is used, with the US probe and needle approximately perpendicular to one another. This requires the US probe to be placed over the eyelid to scan transbulbar, with the needle inserted via the supraorbital fossa. Difficulty in visualising the optic nerve and needle was described in some cases, with one instance (1/40) of optic nerve sheath puncture. The median distance of needle tip to the optic nerve was 3 mm (range 1–7) [21]. This highlights that even with USG, serious complications are still possible with the RB technique, especially with any unexpected movement in a sedated horse.

Compared to the USG RB technique [21], the USG PB technique described here has several advantages. First, an “in plane” technique improves needle visualisation. Second, the US probe and needle are placed at the supraorbital fossa, which would be out of the horse's vision in the live animal. Finally, the target for the PB is distant from vital structures inside the extraocular muscle cone such as the ophthalmic artery and branches, and the optic nerve.

In *Phase 2*, operators with similar levels of experience with both the RB technique and the use of US, but naïve to the USG PB, were used. This was to enable direct comparison of technique success, and to avoid experience level being a confounding factor. The results strongly support the USG PB as being easy to learn and perform correctly, after only one demonstration and with little prior experience. The large difference seen in injection site success between techniques was surprising, certainly the fact that none of the RB injections were in the retrobulbar space. The majority were actually in the peribulbar space. More experienced operators may have increased RB success rate, and the use of cadavers as opposed to live animals could also have made RB more challenging.

Clinically, although these injections were not successfully injected at the target site, they may still have had good effect due to diffusion of local anaesthetic into intraconal and extraconal compartments. This, however, was beyond the scope of this study. A potential surrogate measure of clinical effectiveness could be spread to the orbital fissure, although this is theoretical. In *Phase 2*, contrast spread to the orbital fissure was seen in 6/18 injections into the peribulbar space (4 in the RB group, 2 in the USG PB group). No statistical difference was seen between groups; however, the sample size may be too small to detect one. Spread of injectate to the orbital fissure may be affected by many factors, including injection location (rostral vs. caudal in the peribulbar space), volume used and viscosity of the injectate. The RB group would have had a more caudal injection location than the USG PB group, which may explain the trend of orbital fissure spread seen in our results.

A standard volume of injection (10 mL) was used for both techniques to enable direct comparison between techniques, contrast location and spread. Due to a lack of research into PB in horses, the ideal injection volume to achieve adequate spread is not known. Studies in small animals have used a wide range of volumes from 0.5 mL [8], 3 mL [12], 0.3 mL/kg [11], with one study using an allometric equation to calculate injection volume in dogs ($2.33 \times BW^{0.33}$) [7]. In humans, a volume 2–4 times that used for RB anaesthesia is suggested for PB [14]. It is possible that had a larger injection volume been used, more frequent spread to the orbital fissure may have been seen.

In horses an injection volume of 10 mL is suggested for the RB [6]; however, in this study 8/10 RB were in fact PB. In the clinical setting this may have resulted in incomplete or failed nerve blocks due to inadequate volume to achieve appropriate spread. One disadvantage to increasing injection volume is the association with a short-lived increase in intraocular

pressure seen in small animals [7,11,12]. Further investigation into the optimal injection volume for PB to achieve adequate spread in horses is required.

This study has several limitations. First, it is a cadaveric study and results cannot be directly extrapolated to live animals. However, the frozen thawed cadaver model used has been described previously in multiple papers in this area [8,9,17]. For instance, no evidence of movement of contrast from the peribulbar space to the retrobulbar space was seen in accordance with other studies in canine cadavers [7,8]. However, evidence in live subjects shows free movement of injectate between the extraconal and intraconal space [12,25]. Second, the same volume of injection was used for both techniques, despite evidence in other species suggesting a higher volume being required for PB. Therefore, the effect of a higher volume on contrast spread is not known. Finally, a mixture of 1:1 radiopaque contrast medium (Iohexol [Omnipaque 300 mg-I/mL], GE Healthcare) and saline was used for injection. This dilution of contrast agent was done to reduce viscosity of the injectate; however, the spread of local anaesthetic in a live animal may differ to that of the contrast–saline mixture used.

In conclusion, the USG PB described here was easy to perform, with no apparent complications aside from the difficulty in optimising ultrasound images in two cases. The USG PB could be a superior alternative to RB in horses due to the potential for fewer complications giving a wider scope for use – for example, not only for enucleations, but also facial, eyelid and corneal surgeries, and ocular analgesia. Further studies are required to evaluate optimal injection volume and clinical effect in live horses.

SUPPLEMENTARY MATERIAL

Supplementary Video 1

Ultrasound video highlighting the key ultrasound anatomy seen when performing this nerve block.

[Click here to view](#)

REFERENCES

1. Johnston GM, Eastment JK, Wood J, Taylor PM. The confidential enquiry into perioperative equine fatalities (CEPEF): mortality results of Phases 1 and 2. *Vet Anaesth Analg*. 2002;29(4):159-170.
[PUBMED](#) | [CROSSREF](#)
2. Valverde A. Balanced anesthesia and constant-rate infusions in horses. *Vet Clin North Am Equine Pract*. 2013;29(1):89-122.
[PUBMED](#) | [CROSSREF](#)
3. Schauvliege S, Cuypers C, Michielsen A, Gasthuys F, Gozalo-Marcilla M. How to score sedation and adjust the administration rate of sedatives in horses: a literature review and introduction of the Ghent Sedation Algorithm. *Vet Anaesth Analg*. 2019;46(1):4-13.
[PUBMED](#) | [CROSSREF](#)
4. Pollock PJ, Russell T, Hughes TK, Archer MR, Perkins JD. Transpalpebral eye enucleation in 40 standing horses. *Vet Surg*. 2008;37(3):306-309.
[PUBMED](#) | [CROSSREF](#)
5. Levine JM, Levine GJ, Hoffman AG, Bratton G. Comparative anatomy of the horse, ox, and dog: the brain and associated vessels. *Equine Compend Contin Educ Pract Vet*. 2008;3:153-164.
6. Stoppini R, Gilger BC. Equine ocular examination basic techniques. In: Gilger BC, editor. *Equine Ophthalmology*. 2nd ed. Saint Louis: W.B. Saunders. 2016, 28-29.

7. Shilo-Benjamini Y, Pascoe PJ, Wisner ER, Kahane N, Kass PH, Maggs DJ. A comparison of retrobulbar and two peribulbar regional anesthetic techniques in dog cadavers. *Vet Anaesth Analg*. 2017;44(4):925-932.
[PUBMED](#) | [CROSSREF](#)
8. Viscasillas J, Everson R, Mapletoft EK, Dawson C. Ultrasound-guided posterior extraconal block in the dog: anatomical study in cadavers. *Vet Anaesth Analg*. 2019;46(2):246-250.
[PUBMED](#) | [CROSSREF](#)
9. Mahler S, Betti E, Guintard C. Evaluation of injectate distribution after ultrasound-guided peribulbar injections in canine cadavers. *Vet Anaesth Analg*. 2020;47(5):720-723.
[PUBMED](#) | [CROSSREF](#)
10. Ahn J, Jeong M, Lee E, Kim S, Park S, Park S, et al. Effects of peribulbar anesthesia (sub-Tenon injection of a local anesthetic) on akinesia of extraocular muscles, mydriasis, and intraoperative and postoperative analgesia in dogs undergoing phacoemulsification. *Am J Vet Res*. 2013;74(8):1126-1132.
[PUBMED](#) | [CROSSREF](#)
11. Wagatsuma JT, Deschk M, Floriano BP, Ferreira JZ, Fioravanti H, Gasparello IF, et al. Comparison of anesthetic efficacy and adverse effects associated with peribulbar injection of ropivacaine performed with and without ultrasound guidance in dogs. *Am J Vet Res*. 2014;75(12):1040-1048.
[PUBMED](#) | [CROSSREF](#)
12. Shilo-Benjamini Y, Pascoe PJ, Maggs DJ, Pypendop BH, Johnson EG, Kass PH, et al. Comparison of peribulbar and retrobulbar regional anesthesia with bupivacaine in cats. *Am J Vet Res*. 2014;75(12):1029-1039.
[PUBMED](#) | [CROSSREF](#)
13. Ripart J, Lefrant JY, Prat-Pradal D, Vivien B, Eledjam JJde La Coussaye JE. Peribulbar versus retrobulbar anesthesia for ophthalmic surgery: an anatomical comparison of extraconal and intraconal injections. *Anesthesiology*. 2001;94(1):56-62.
[PUBMED](#) | [CROSSREF](#)
14. Nouvellon E, Cuvillon P, Ripart J, Viel EJ. Anaesthesia for cataract surgery. *Drugs Aging*. 2010;27(1):21-38.
[PUBMED](#) | [CROSSREF](#)
15. Shilo-Benjamini Y. A review of ophthalmic local and regional anesthesia in dogs and cats. *Vet Anaesth Analg*. 2019;46(1):14-27.
[PUBMED](#) | [CROSSREF](#)
16. Campoy L, Read MR. *Small Animal Regional Anesthesia and Analgesia*. 1st ed. Ames: Wiley Blackwell; 2013.
17. O'Neill HD, Garcia-Pereira FL, Mohankumar PS. Ultrasound-guided injection of the maxillary nerve in the horse. *Equine Vet J*. 2014;46(2):180-184.
[PUBMED](#) | [CROSSREF](#)
18. Campoy L, Morris TB, Ducharme NG, Gleed RD, Martin-Flores M. Unilateral cervical plexus block for prosthetic laryngoplasty in the standing horse. *Equine Vet J*. 2018;50(6):727-732.
[PUBMED](#) | [CROSSREF](#)
19. Küls N, Trujanovic R, Otero PE, Larenza-Menzies MP. Ultrasound-guided transversus abdominis plane block in Shetland ponies: a description of a three-point injection technique and evaluation of potential analgesic effects. *J Equine Vet Sci*. 2020;90:102994.
[PUBMED](#) | [CROSSREF](#)
20. Lewis SR, Price A, Walker KJ, McGrattan K, Smith AF. Ultrasound guidance for upper and lower limb blocks. *Cochrane Database Syst Rev*. 2015;(9):CD006459.
[PUBMED](#) | [CROSSREF](#)
21. Morath U, Luyet C, Spadavecchia C, Stoffel MH, Hatch GM. Ultrasound-guided retrobulbar nerve block in horses: a cadaveric study. *Vet Anaesth Analg*. 2013;40(2):205-211.
[PUBMED](#) | [CROSSREF](#)
22. Badawy AM, Eshra EA. Development of an ultrasound-guided technique for retrobulbar nerve block in dromedary camels: a cadaveric study. *Vet Anaesth Analg*. 2018;45(2):175-182.
[PUBMED](#) | [CROSSREF](#)
23. Dyce KM, Sack WO, Wensing CJ. *Textbook of Veterinary Anatomy*. 3rd ed. Ames: W.B. Saunders; 2002.
24. Hermans H, Veraa S, Wolschrijn CF, Van Loon JP. Local anaesthetic techniques for the equine head, towards guided techniques and new applications. *Equine Vet Educ*. 2019;31(8):432-440.
[CROSSREF](#)
25. Ropo A, Nikki P, Ruusuvaara P, Kivisaari L. Comparison of retrobulbar and periocular injections of lignocaine by computerised tomography. *Br J Ophthalmol*. 1991;75(7):417-420.
[PUBMED](#) | [CROSSREF](#)
26. Martin-Flores M. Neuromuscular blocking agents and monitoring in the equine patient. *Vet Clin North Am Equine Pract*. 2013;29(1):131-154.
[PUBMED](#) | [CROSSREF](#)