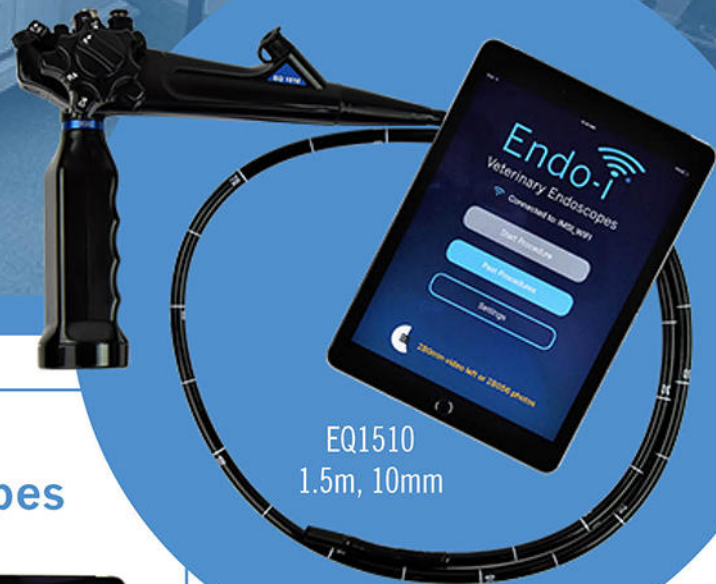

SOMETIMES OLD SCHOOL ISN'T COOL

There's a *Better*
Way to Scope...



EQ1510
1.5m, 10mm

Endo-i[®] Wireless HD Endoscopes

- ▶ No Bulky Towers
- ▶ Easy to Transport
- ▶ 3 Models Available (1m, 1.5m, 3m)
- ▶ Tablet & App Included



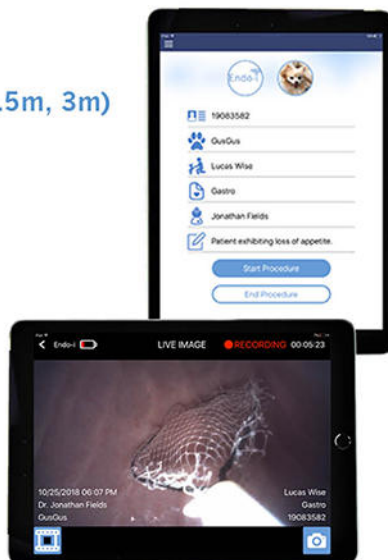
EASE-OF-USE



MANAGE PATIENT
INFORMATION



EXPORT
PROCEDURAL
DATA



Patented Technology



STERIS

Animal Health

1.844.540.9810
sterisanimalhealth.com

CASE REPORT

Delayed onset vagus nerve paralysis after occipital condyle fracture in a horse

Tamara Martin-Giménez¹  | Antonio M. Cruz^{1,2} | Agustín Barragán³ |
 Estefanía Montero³ | Pedro G. Sanchez¹ | Guillermo Caballero¹ | Ignacio Corradini^{1,2} 

¹Veterinary Teaching Hospital, Faculty of Veterinary Sciences, Universidad Cardenal Herrera CEU, CEU Universities, Valencia, Spain

²Department of Animal Medicine and Surgery, Faculty of Veterinary Sciences, Universidad Cardenal Herrera CEU, CEU Universities, Valencia, Spain

³Pathological Anatomy Service, Faculty of Veterinary Sciences, Universidad Cardenal Herrera CEU, CEU Universities, Valencia, Spain

Correspondence

Tamara Martin-Giménez, Veterinary Teaching Hospital, Faculty of Veterinary Sciences, Universidad Cardenal Herrera CEU, CEU Universities, C/ Santiago Ramón y Cajal s/n, 46115 Alfara del Patriarca, Valencia, Spain. Email: tamara.martin@uchceu.es

Abstract

Occipital condylar fractures (OCFs) causing delayed onset lower cranial nerve paralysis (LCNPs) are rare. We present a 7-year-old Friesian horse with delayed onset dysphagia caused by vagus nerve (CNX) paralysis and suspicion of glossopharyngeal nerve (CNIX) paralysis developed several days after a minor head injury. Endoscopic examination revealed right laryngeal hemiplegia and intermittent dorsal displacement of the soft palate. An area of submucosal hemorrhage and bulging was appreciated over the dorsal aspect of the medial compartment of the right guttural pouch. Radiological examination of the proximal cervical region showed rotation of the atlas and the presence of a large bone fragment dorsal to the guttural pouches. Occipital condyle fracture with delayed onset cranial nerve paralysis was diagnosed. Delayed onset cranial nerve paralysis causing dysphagia might be a distinguishable sign of OCF in horses. Delayed onset dysphagia after head injury should prompt equine clinicians to evaluate the condition of the atlanto-occipital articulation and skull base.

KEYWORDS

cranial nerves, guttural pouch, laryngeal neuropathy, neurological signs, neuropraxia, trauma

1 | CASE

Traumatic injuries to the head are relatively common in horses.^{1,2} These usually occur after falling backward, kicks from other horses, or running into stationary objects.¹⁻³ Trauma to the skull might produce lesions leading to neurological disorders.^{2,3}

Occipital condylar fractures (OCFs) are a unique unusual occurrence among craniocervical injuries widely described in human medicine.⁴⁻⁶ In people, lower cranial nerve palsies (LCNPs) occur as a direct consequence of a fractured occipital condyle. Cranial nerve (CN) deficits can manifest immediately after trauma, but can also appear with a delay in time.⁷ Delayed LCNP is a rare complication of OCF that

develops in approximately 1% of the cases. Unilateral hypoglossal nerve (CNXII) paralysis occurs most commonly.⁸ Occipital condyle fractures occur mainly after severe head trauma accompanied by profound mentation changes. However, OCFs also occur after minor head injuries with a normal level of consciousness.⁷

Here, we describe a case of a horse in which a complete OCF with vagus nerve (CNX) dysfunction and suspicion of glossopharyngeal nerve (CNIX) involvement developed several days after suffering a minor head injury.

1.1 | Case history

A 7-year-old Friesian intact male was presented to the Hospital Clínico Veterinario CEU UCH with dysphagia of 36 hours duration. The owners reported a traumatic incident while the horse was being shod

Abbreviations: CNIX, glossopharyngeal nerve; CNs, cranial nerves; CNX, vagus nerve; CNXI, accessory nerve; CNXII, hypoglossal nerve; LCNPs, lower cranial nerve palsies; NG, nasogastric; OCFs, occipital condylar fractures.

This is an open access article under the terms of the Creative Commons Attribution-NonCommercial License, which permits use, distribution and reproduction in any medium, provided the original work is properly cited and is not used for commercial purposes.

© 2019 The Authors. *Journal of Veterinary Internal Medicine* published by Wiley Periodicals, Inc. on behalf of the American College of Veterinary Internal Medicine.

5 days before dysphagia became evident. According to the owners, the horse reared back and took a couple of strides forward, hitting the right side of its head against a wall. A small abrasion over the zygomatic arch was noted, but the farrier and the owners did not notice any other abnormalities and considered the trauma to be minor. The horse had been in good health before the traumatic event. During the days after head trauma, the horse was slightly dull, but continued to eat and drink normally and to perform his daily activities. Five days after the trauma, the horse had signs of acute onset dysphagia (food and water coming out of the nostrils). The referring veterinarian described difficulty in passing the nasogastric (NG) tube and suspected esophageal obstruction and secondary aspiration pneumonia. The horse was administered penicillin and gentamicin and nonsteroidal anti-inflammatory drugs (flunixin-meglumine). The next day, the horse continued to show signs of dysphagia and was referred to the hospital.

1.2 | Clinical findings

Upon admission, the horse was bright, alert, and was in good body condition (7/9). The heart rate was 46 beats/min, respiratory rate 21 breaths/min, and rectal temperature was 38.0°C. During auscultation of the thorax, low-pitched wheezes and increased bronchovesicular sounds were noted on the right ventrocaudal lung field. The horse had ptialism and a foamy nasal discharge with food contents. Upon digital palpation of the poll and the proximal neck area, there was a marked increase in the space between the right ramus of the mandible and the right wing of the atlas compared with the left side. Bending of the neck to the right side elicited a marked painful response. A complete neurological examination revealed dysphonia, dysphagia, and an absent thoraco-laryngeal reflex over the right side. However, the horse had normal mentation and behavior and did not show any signs of ataxia on complete dynamic neurological examination performed by a board certified equine internal medicine specialist.

Endoscopic examination (without sedation) of the upper airway revealed a right laryngeal hemiplegia grade 4/4⁹ and intermittent dorsal displacement of the soft palate. There was an absent gag reflex upon stimulation of the pharynx with the tip of the endoscope, the biopsy forces, or with water passed through the biopsy channel on the right side and was inconsistent on the left side of the pharynx. Feed-tinged saliva in the pharynx and proximal third of the trachea was also observed. Upon endoscopic examination of the right guttural pouch, an area of submucosal hemorrhage and bulging was appreciated over the dorsal aspect of the medial compartment in the vicinity of the temporohyoid articulation. During esophagoscopy, peristaltic contractions of the distal part of the esophagus appeared to be reduced. On advancing the gastroscope, there was increasing resistance to the passage of the scope into the distal end of the esophagus which made it difficult to reach the stomach.

The results of hematological analysis were within normal limits and plasma biochemistry revealed mild increases in creatinine (1.89 mg/dL, normal 0.60-1.80 mg/dL), alanine-transferase (ALT; 583 IU/L, normal 109-315 IU/L), and albumin (4.3 g/dL, normal 2.5-4.2 g/dL).

Standing latero-lateral and ventro-dorsal radiographs of the poll area and proximal cervical vertebral column showed an abnormal position of the atlas and the presence of a bone fragment over the dorsal aspect of the guttural pouches (Figure 1).

Ultrasonographic examination (X-Porte Sonosite) of the retro-mandibular and poll areas revealed the presence of an echogenic structure with posterior acoustic shadow caudally and medially to the proximal aspect of the right ramus of the mandible. Ultrasonographic examination of the thorax revealed an increased number of "comet-tail" artifacts on the right ventro-cranial hemithorax compared to the left side. Computed tomography was considered to be the best diagnostic procedure but that option was discarded because of the risks associated with anesthesia induction and recovery in the face of suspected atlas and occipital fractures. Electromyography of the right trapezoid muscle on the day 7 of hospitalization (12 days after head trauma) showed no abnormalities or differences with the left trapezoid muscle. Electromyography of the right dorsal crycoaritenoid muscle revealed a fibrillation pattern with sharp waves and the characteristic burst sounds being heard during the procedure.

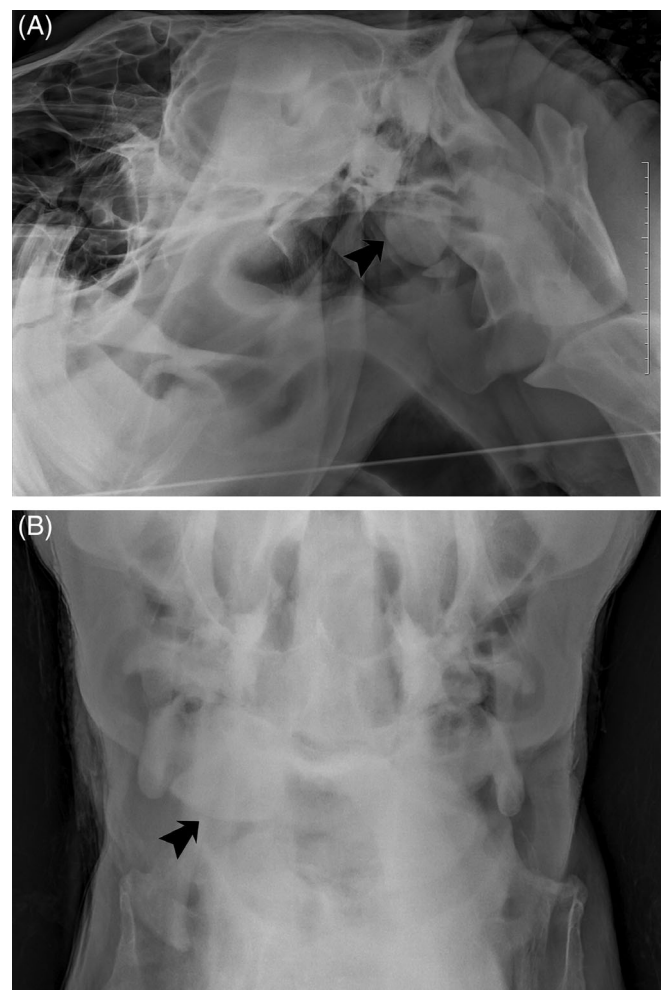


FIGURE 1 A, Latero-lateral and B, ventro-dorsal radiographs of the poll area and proximal cervical vertebral column that show rotation of the atlas and the presence of a bone fragment over the dorsal aspect of the guttural pouch (black arrows)

1.3 | Diagnosis

Based on history, clinical, and radiological findings, a diagnosis of functional pharyngeal dysphagia because of delayed CNX paralysis associated with atlas and occipital bone fractures was reached. In addition, aspiration pneumonia was diagnosed.

2 | CASE PROGRESSION, MANAGEMENT, AND TREATMENT

2.1 | Treatment

The horse was treated conservatively with broad spectrum antibiotic treatment, nonsteroidal anti-inflammatory drugs, enteral nutrition via a stomach tube, and intravenous administration of fluids.

Initial progression was poor: the horse failed to tolerate enteral nutrition and showed intermittent bouts of mild to moderate abdominal pain associated with the administration of enteral feeding. Pain would abate upon removal of gastric contents by gastric lavage via a NG tube, consisting mainly of the previously administered meal. The horse was started on pro-kinetic treatment with metoclopramide given SC (0.08 mg/kg bwt q8h) and total parenteral nutrition (Nutriflex Lipid Peri, Braun, Spain). After initiation of metoclopramide treatment, the horse started tolerating enteral nutrition. Progression over the following days, however, was poor: the horse continued to present dysphagia and weight loss, and developed diarrhea.

Follow-up endoscopic examination showed a persistent right laryngeal paralysis (grade 4/4) and intermittent dorsal displacement of soft palate. The abnormalities previously observed over the dorsal aspect of medial compartment of right guttural pouch were unchanged.

2.2 | Outcome

After 15 days of hospitalization, and based on the poor response to treatment and the poor prognosis, the owners decided to euthanize the animal.

2.2.1 | Postmortem findings

Cranio-cervical *postmortem* CT scan revealed a displaced fracture of the right occipital condyle at its base and a small defect of the fovea of the atlas. Bony fragments were observed around the atlanto-occipital articulation and the distracted occipital condyle fragment on the right side (Figure 2).

Gross pathological examination showed extensive bruising, hemorrhage, and edema involving the muscles and soft tissues of the right side of the neck on the affected area. Upon further dissection, it was evidenced that the condyle was completely separated from the skull and was displaced rostrally and ventrally, although the ligaments of the atlanto-occipital articulation were intact. Focal areas of hemorrhage around the right condyle and the dorsal articular surface of the atlas were also noted. The caudo-ventral area of the fractured condyle showed fragmentation of the bony surface. The atlas showed a

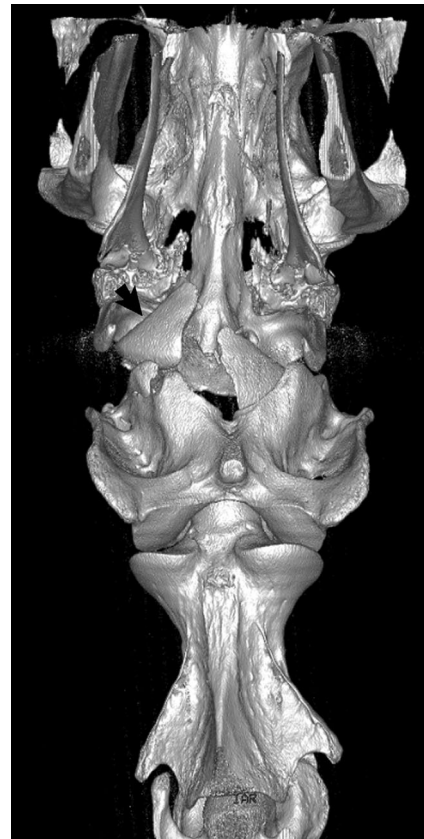


FIGURE 2 *Postmortem* CT in which the displaced fractured right occipital condyle is observed (black arrow). A small defect of the fovea of the atlas is also evident

superficial loss of bone on the dorsal aspect of the cranial joint fovea of approximately 1 cm in diameter. For the histopathological study of the occipital condyle, the tissue was decalcified with nitric acid as previously described.¹⁰ Histological examination of the fractured condyle showed changes associated with hemorrhage, but there were no changes suggestive of an underlying pathology. Histological examination of the right cricoarytenoid muscle showed changes compatible with neurogenic muscle atrophy, necrosis, lymphocyte, and mild subacute neutrophil myositis with loss of the normal organization of muscle fibers (Figure 3). Wallerian degeneration characterized by dilated myelin sheaths with spheroids was present in the right recurrent laryngeal nerve and peripheral nerves adjacent to the *rectus capitis lateralis* muscle. The spinal cord showed no pathological changes at the level of the atlanto-occipital articulation.

The presence of suppurative bronchopneumonia at the right cranial lung lobe and moderate alveolar edema was also observed. A 5-cm-diameter stomach diverticulum over the great curvature of the nonglandular portion was observed.

3 | DISCUSSION

In the case presented here, an uncommon OCF causing a delayed onset of LCNPs was diagnosed several days after head trauma. This

type of fracture is considered to be an unusual injury in humans with an estimated frequency of 1%-3% of cases with closed craniocervical lesions.⁶ In horses, trauma to the occipital region is described in association with nuchal crest, basisphenoid, and paracondylar process fractures.^{3,11,12} In 2 retrospective studies involving 34 and 47 horses with traumatic head injury, neurological deficits were most commonly associated with basisphenoid/basioccipital bone fractures.^{2,13} None of these horses were reported to have an OCF.

In human patients, OCF can be complicated with LCNPs.¹⁴ Several clinical syndromes are recognized in humans depending on which CNs were simultaneously implicated.¹⁵ In the case described in this report, damage to the CNX could explain neurological signs such as dysphagia, right laryngeal paralysis, dysphonia, and lack of a gag reflex. Most of these clinical signs are frequently identified in human patients with LCNPs associated to OCF.^{7,14,16} However, few case reports describe an isolated impairment of the CNX in people.¹⁴ It is not clear whether there was impaired CNIX function in the present case. Both, the CNIX and the CNX provide sensory innervation to the pharynx.¹⁷ In human

patients, it can be difficult to diagnose isolated CNIX dysfunction, and this differentiation does not appear to be straightforward in horses either.¹⁷ In 1 retrospective study including 47 horses with head trauma, dysfunction of CNs IX and X was reported in 1 of them. However, the authors did not specify whether there was a lesion affecting the occipital condyle or not.¹³

In horses, the lower CNs originate close to each other in the brain stem and exit through the *foramen jugulare* (CNs IX, X, XI) and hypoglossal canal (CNXII)¹⁸ (Figure 4A,B). The *foramen jugulare* is closely related to the occipital condyle. In the case presented here, nerve damage was hypothesized to have occurred at a point near the exit from the skull because of the evident involvement of CNX pharyngeal branches. In human patients with OCF, the accessory nerve (CNXI) is commonly implicated along with CNs IX and X (Jugular or Vernet's syndrome).¹⁵ In the present case, CNXI function appeared to be intact as evidenced by the lack of electromyographic changes over the right trapezoid muscle and the absence of muscle atrophy both clinically and on *postmortem* examination. The CNs IX, X, and XI share the same outlet from the skull, however once they exit, CNIX and CNX follow a cranio-ventral route. In contrast, CNXI travels caudally soon after leaving the skull.¹⁹ This difference in pathways could explain the lack of involvement of CNXI in this case.

When LCNPs occur as a consequence of an OCF, dysfunction develops acutely in most cases, but one-third of affected human patients have a delayed onset of clinical signs,⁵ having been described from a few days up to several weeks.⁸ In the case presented here, dysphagia became evident several days after the traumatic event in agreement with the time-lag to onset of CN dysfunction seen in some human patients. Although different theories have been proposed, the exact mechanism for delayed onset nerve paralysis remains unclear.⁵ Nerve transection by a displaced bone fragment would cause immediate onset of clinical signs. Delayed onset nerve paralysis has been hypothesized to be caused by progressive nerve edema and related ischemia. These events result in hemorrhage and hematoma formation compressing these nerves, ultimately leading to neuropraxia.⁸ In the case presented here, there were focal areas of hemorrhage and tissue edema around the lesion as noted during *postmortem* examination. In

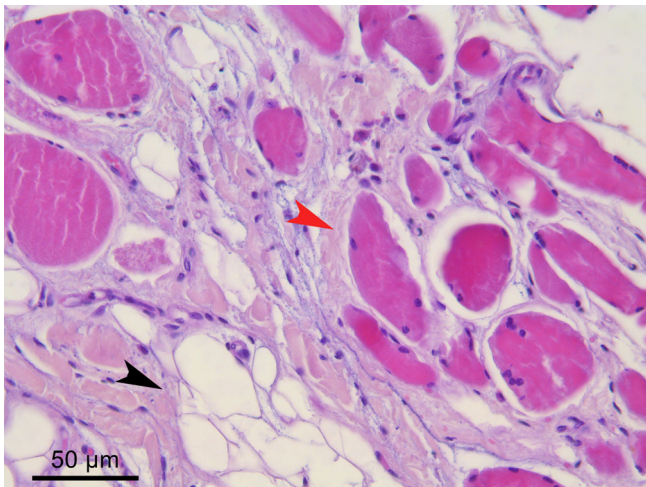


FIGURE 3 Microscopic image (hematoxylin-eosin stain $\times 40$) of the right cricoarytenoid muscle that shows massive adipocyte infiltration (black arrow) and atrophy (red arrow)

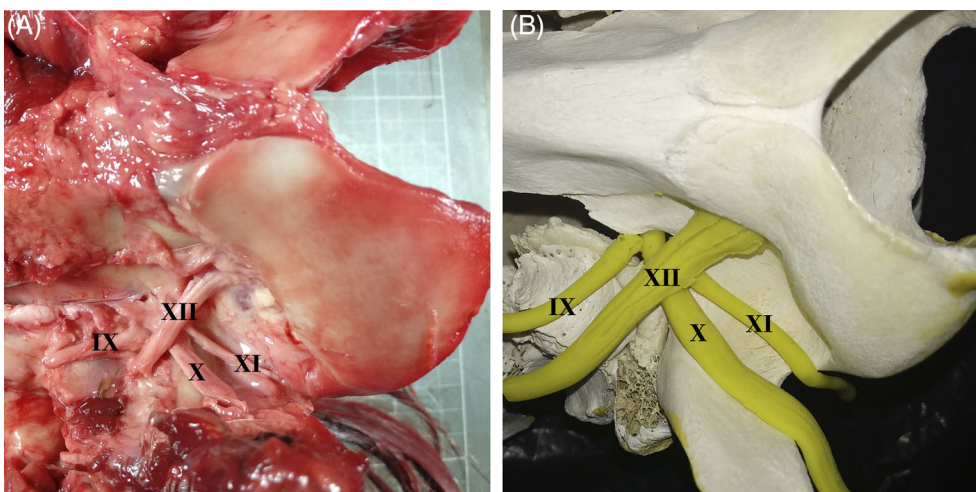


FIGURE 4 Ventral view of the caudal aspect of the skull showing the extracranial pathways of the caudal cranial nerves IX, X, XI, and XII in A, a dissection specimen and in B, an anatomical model

addition, the fractured occipital condyle was displaced rostral and ventrally, in contact with the dorsal aspect of the medial compartment of the right guttural pouch. Direct nerve compression by the displaced bone fragment could have also played a role.¹⁴ A combination of both mechanisms could have contributed significantly to the delayed onset CN damage observed in this horse. Other possible mechanisms of CN injury have been proposed for specific CNs. For instance, delayed onset oculomotor nerve dysfunction has been proposed to occur secondary to stretching because of differential movement between the brainstem and supratentorial structures during head trauma. However, this mechanism is most likely related to that CN because of specific anatomic features.²⁰

During postmortem examination, no involvement of the brainstem was detected, supporting our observations that CN damage occurred extracranially. In addition, denervation atrophy and wallerian degeneration of the nerves supplying the right *cricoarytenoid dorsalis* muscle and the *rectus capitis lateralis* muscle of the head were observed. Macroscopically the right *rectus capitis lateralis* muscle showed a change in coloration because of fat infiltration and a decrease in size (Figure 5). Denervation of the first would be explained by damage to the recurrent laryngeal nerve as it exits the caudal brainstem as part of the CNX.^{18,19} However, the *rectus capitis lateralis* muscle of the head is innervated by the dorsal branch of the first cervical nerve which exists from the lateral vertebral foramen situated on the wing of the atlas.¹⁹ The case reported here had a marked rotation of the atlas as observed on latero-lateral radiographs and a fracture at a short distance from the lateral foramen (2 cm). It is plausible that edema, hemorrhage, and impingement or stretching of the first cervical nerve because of rotation of the atlas could have contributed to its dysfunction.

In the case presented here, partial gastric and esophageal dysfunctions were also suspected. Clinically relevant esophageal dysfunction might be well related to vagus denervation as vagal activity is an

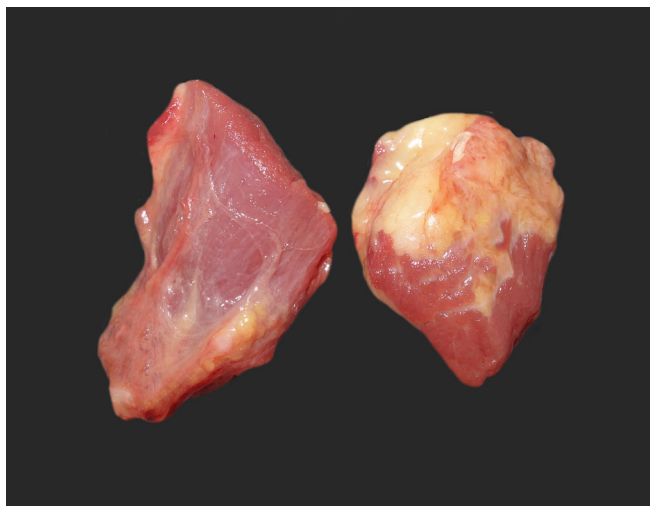

FIGURE 5 Macroscopic image comparing the right and left cranial *rectus capitis lateralis* muscles. A change in coloration caused by fat infiltration and a decrease in size of the right *rectus capitis lateralis* muscle are visible

essential part of normal esophageal peristaltic mechanisms.²¹ Unilateral CNX damage can also cause stomach acid secretion disorders and transient delayed gastric emptying.²² Inadvertent complete unilateral vagotomy can lead to gastric dysmotility in human patients.²³ However, autonomic disturbances are not consistently encountered unless bilateral damage is present.²⁴ Even then, dysphagia and vocal cord paralysis might be the only abnormalities detected.²⁵ It has been speculated that this variation in clinical signs could be related to the extent of CNX damage.²⁴

4 | CONCLUSIONS AND CLINICAL IMPORTANCE

In conclusion, OCF with delayed onset lower cranial nerve deficits, although very uncommon, should be considered as a possible sequel to head trauma in horses. This case should encourage clinicians to consider these types of fractures in arriving at a differential diagnosis of functional dysphagia in horses. Considering the severe consequences of this type of injury, delayed signs of CN paralysis should prompt equine clinicians to evaluate the condition of the atlanto-occipital articulation and skull base.

ACKNOWLEDGMENTS

The authors thank Alejandro Luján Feliú and Alba Farré for their contribution to the diagnosis through electrophysiological testing. The case was partially presented at the “XLI reunion de la sociedad Española de anatomía patológica veterinaria,” June 2018, Murcia, Spain.

CONFLICT OF INTEREST DECLARATION

Authors declare no conflict of interest.

OFF-LABEL ANTIMICROBIAL DECLARATION

Authors declare no off-label use of antimicrobials.



INSTITUTIONAL ANIMAL CARE AND USE COMMITTEE (IACUC) OR OTHER APPROVAL DECLARATION

Authors declare no IACUC or other approval was needed.

HUMAN ETHICS APPROVAL DECLARATION

Authors declare human ethics approval was not needed for this study.

ORCID

Tamara Martin-Giménez  <https://orcid.org/0000-0003-4558-0048>
Ignacio Corradini  <https://orcid.org/0000-0002-4053-8863>

REFERENCES

1. Ramirez O, Jorgensen JS, Thrall DE. Imaging basilar skull fractures in the horse: a review. *Vet Radiol Ultrasound*. 1998;39:391-395.
2. Feary DJ, Magdesian KG, Aleman MA, Rhodes DM. Traumatic brain injury in horses: 34 cases (1994–2004). *J Am Vet Med Assoc*. 2007; 231:259-266.
3. Lischer CJ, Walliser U, Witzmann P, Eser MW, Ohlerth S. Fracture of the paracondylar process in four horses: advantages of CT imaging. *Equine Vet J*. 2005;37:483-487.
4. Huang D-W, Tai S-H, Hung Y-C, Fang V-K, Lee M-Y, Lee E-J. A rare occipital condyle fracture in a patient with a minor head injury. *Kaohsiung J Med Sci*. 2009;25:342-346.
5. Karam YR, Traynelis VC. Occipital condyle fractures. *Neurosurgery*. 2010;66:56-59.
6. Theodore N, Aarabi B, Dhall SS, et al. Occipital condyle fractures. *Neurosurgery*. 2013;72:106-113.
7. Legros B, Fournier P, Chiaroni P, Ritz O, Fuscuardi J. Basal fracture of the skull and lower (IX, X, XI, XII) cranial nerves palsy: four case reports including two fractures of the occipital condyle—a literature review. *J Trauma Acute Care Surg*. 2000;48:342.
8. Vadivelu S, Masood Z, Krueger B, et al. Long-term resolution of delayed onset hypoglossal nerve palsy following occipital condyle fracture: case report and review of the literature. *J Craniovertebral Junction Spine*. 2017;8:149-152.
9. Ducharme N. Grade system for equine laryngeal function. In: Dixon PM, Robinson E, Wade JF, eds. *Proceedings of a Workshop on Equine Recurrent Laryngeal Neuropathy*. Havemeyer Foundation Monograph Series No. 11. Newmarket, UK: R & W Publications; 2003:93-97.
10. Savi FM, Briery GI, Baldwin J, Theodoropoulos C, Woodruff MA. Comparison of different decalcification methods using rat mandibles as a model. *J Histochem Cytochem*. 2017;65:705-722.
11. Voigt A, Saulez MN, Donnellan CM. Nuchal crest avulsion fracture in 2 horses: a cause of headshaking: clinical communication. *J S Afr Vet Assoc*. 2009;80:111-113.
12. Sweeney CR, Freeman DE, Sweeney RW, Rubin JL, Maxson AD. Hemorrhage into the guttural pouch (auditory tube diverticulum) associated with rupture of the longus capitis muscle in three horses. *J Am Vet Med Assoc*. 1993;202:1129-1131.
13. Tyler CM, Davis RE, Begg AP, Hutchins DR, Hodgson DR. A survey of neurological diseases in horses. *Aust Vet J*. 1993;70:445-449.
14. Bozkurt G, Hazer B, Yaman ME, Akbay A, Akalan N. Isolated paralysis of glossopharyngeal and vagus nerve associated with type II occipital condyle fracture: case report. *Childs Nerv Syst*. 2010;26:719-722.
15. Finsterer J, Grisold W. Disorders of the lower cranial nerves. *J Neurosci Rural Pract*. 2015;6:377-391.
16. Chen CT, Liu ZH, Lee ST, Tu PH. Delayed unilateral vocal cord paralysis caused by minor head trauma. *Formos J Surg*. 2016;49:230-232.
17. Erman AB, Kejner AE, Hogikyan ND, Feldman EL. Disorders of cranial nerves IX and X. *Seminars in Neurology*. Stuttgart, Germany: Thieme Medical Publishers; 2009:85.
18. De Lahunta A, Glass EN, Kent M. *Veterinary Neuroanatomy and Clinical Neurology-E-Book*. St. Louis, Mo: Elsevier Health Sciences; 2014.
19. Budras K-D, Sack WO, Rock S. *Anatomy of the Horse: An Illustrated Text*. Hannover, Germany: Schlütersche GmbH & Co.; 2003.
20. Nakagawa Y, Toda M, Shibao S, Yoshida K. Delayed and isolated oculomotor nerve palsy following minor head trauma. *Surg Neurol Int*. 2017;8:20.
21. Goyal RK, Chaudhury A. Physiology of normal esophageal motility. *J Clin Gastroenterol*. 2008;42:610-619.
22. Gutierrez LV, Kocak N, Cox AG. Alimentary transit and supersensitivity after vagotomy in the rat. *Gut*. 1971;12:625-628.
23. Tobi M, Holtz T, Carethers J, Owyang C. Delayed gastric emptying after laparoscopic anterior highly selective and posterior truncal vagotomy. *Am J Gastroenterol*. 1995;90:810-811.
24. Yoo SD, Kim DH, Lee SA, Joo HI, Yeo JA, Chung SJ. Bilateral cranial IX and X nerve palsies after mild traumatic brain injury. *Ann Rehabil Med*. 2016;40:168-171.
25. Lehn AC, Lettieri J, Grimley R. A case of bilateral lower cranial nerve palsies after base of skull trauma with complex management issues: case report and review of the literature. *Neurologist*. 2012;18:152-154.

How to cite this article: Martin-Giménez T, Cruz AM, Barragán A, et al. Delayed onset vagus nerve paralysis after occipital condyle fracture in a horse. *J Vet Intern Med*. 2019; 1–6. <https://doi.org/10.1111/jvim.15581>