

Case 16041

Infiltration of the medial rectus muscle as the first manifestation in a primary orbital lymphoma

Oprisan AAI¹, Barreda-Solana M¹, Diaz-Cespedes RA², Piqueras-Olmeda R¹

¹ Radiology Service, Hospital Universitario y Politécnico La Fe, Valencia, Spain.

² Ophthalmology Service, Hospital Manises, Valencia, Spain.

Hospital Universitario y Politécnico La Fé; Av. Fernando Abril Martorell, 106 Torre E, Planta 0, Despacho CEIB 46026 Valencia, Spain; Email: oprisan.anca@gmail.com

Section: Head & Neck Imaging

Published: 2018, Oct. 21

Patient: 70 year(s), female

Clinical History

A 70-year-old woman presented with a 3 months history of persistent unilateral headache with orbital pain irradiation. Multiple analgesic treatments were used with no pain relief.

Imaging Findings

On ocular examination, she had no-restricted ocular motility but gradually progressive pain on adduction of the right eye. No proptosis or loss of vision were found. The left eye and ocular adnexa were normal. Previous history of breast cancer diagnosed 3 years ago was referred without metastasis. Currently the patient is disease-free and without any undergoing treatment. Her family history was noncontributory.

The contrast-enhanced CT scan of the orbits showed a marked thickening of the internal rectus muscle (IRM) of the right orbit (Fig1a-b). The MRI with and without ivc showed a thickened muscle with isointens signal in both T1, T2 and STIR sequences with homogenous contrast enhancement and restricted diffusion (Fig2a-2g). Otherwise, normal findings. The study was completed with an FDG/PET-CT, that confirmed the high metabolism in the topography of the IRM (Fig2e).

Discussion

Lymphoid masses in the orbit, conjunctiva, lacrimal gland and eyelids are usually low-grade tumors, representing 10-15% of all orbital tumors according to different series and up to 55% of the orbital malignancies.

It can be a primary lymphoma or a systemic infiltration of it (2, 3). Usually, primary lymphoma affects lacrimal glands and less frequently it may present like a diffuse infiltrative form of the extraocular muscles (3). Normally appears slightly hyperdense on CT and iso- or hypointense on MRI T1 and T2 sequences.

The breast cancer history pointed to a metastatic lesion since, with the orbital fat, the ocular muscles are the most frequent localization (2, 3). Metastatic or other malignant lesions are usually ill-defined and have high signal on T2 and STIR sequences or lower ADC values (4).

The clinical presentation, with sub-acute orbital pain and the muscle thickening, were in favor of a pseudotumor diagnosis. On MR images, inflammatory pseudotumors are usually isointense to hypointense relative to muscle on T2-weighted images and have an increased attenuation into dynamic late phase.

The less probable disease was the thyroid orbitopathy. Typically, it produces painless bilateral proptosis with bilateral enlargement of the extra-ocular muscles sparing the muscle tendons insertion (5).

To help distinguish the lymphoma from the other diagnosis we can use the ADC map. It was demonstrated that it has a significantly lower ADC value than the other orbital diseases (6).

The image studies are helpful in order to define the extent and the accurate location of the ocular disease, to determinate if it is accessible for a biopsy and, most important, they are narrowing down the possibilities for the differential diagnosis. Very often, a biopsy is necessary to make the precise diagnosis and facilitate an appropriate treatment, like in this case. Adminstrating chemotherapy or radiotherapy for a primary ocular lymphoma in most cases has a good response and a high cure rate(4, 5), although it was described that 30% of the patients are at risk of developing a systemic lymphoma after 10 years from the initial diagnosis(3).

After performing a biopsy for our patient, the results revealed a low-grade B-cell lymphoma infiltrating the IRM. The bone marrow aspiration was normal, discarding the possibility of systemic lymphoma. Radiotherapy was administrated.

Our patient had a great response to the radiotherapy and currently she is disease-free with normal nuclear and image studies(Fig3).

Written informed patient consent for publication has been obtained.

Final Diagnosis

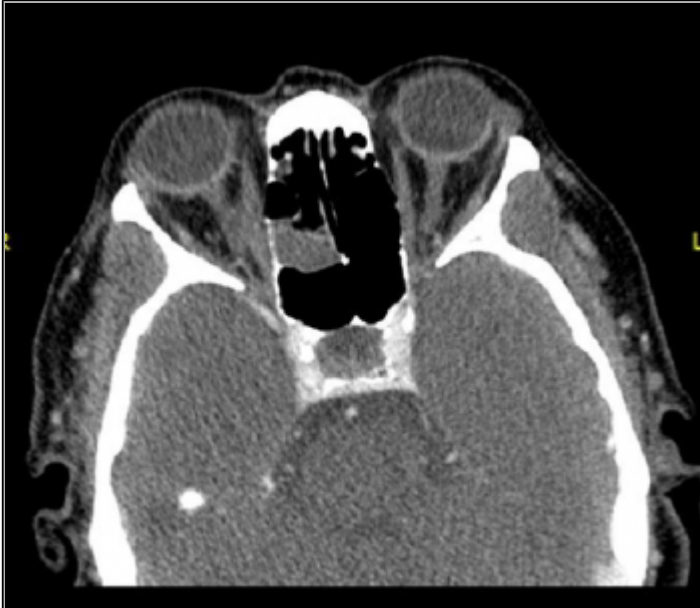Orbital primary Non-Hodgkin B-cell lymphoma

Differential Diagnosis List

Breast cancer orbital metastasis, Idiopathic orbital inflammatory syndrome, Thyroid orbitopathy

Figures

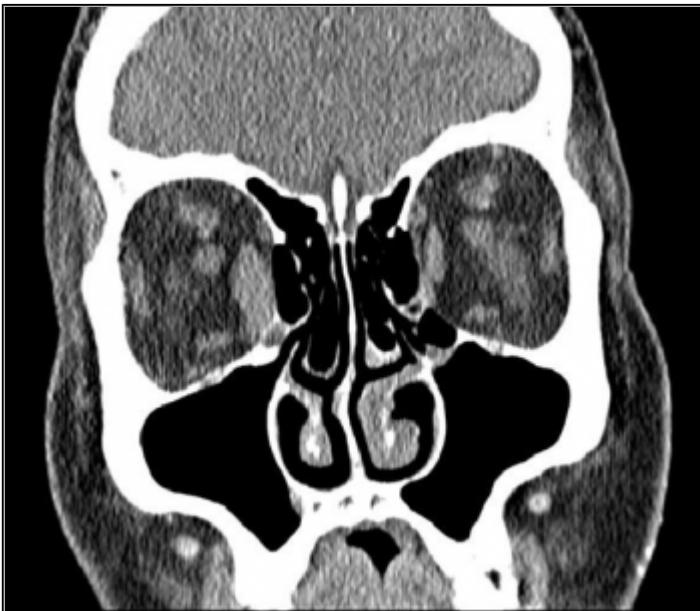
Figure 1 Orbits contrast-enhanced CT scan



CT-axial image. A marked thickening of the internal rectus muscle of the right orbit is seen.

© ACIM, Hospital Universitario y Politécnico La Fe, Valencia, Spain.

Area of Interest: Head and neck;
Imaging Technique: CT;
Procedure: Contrast agent-intravenous;
Special Focus: Lymphoma;

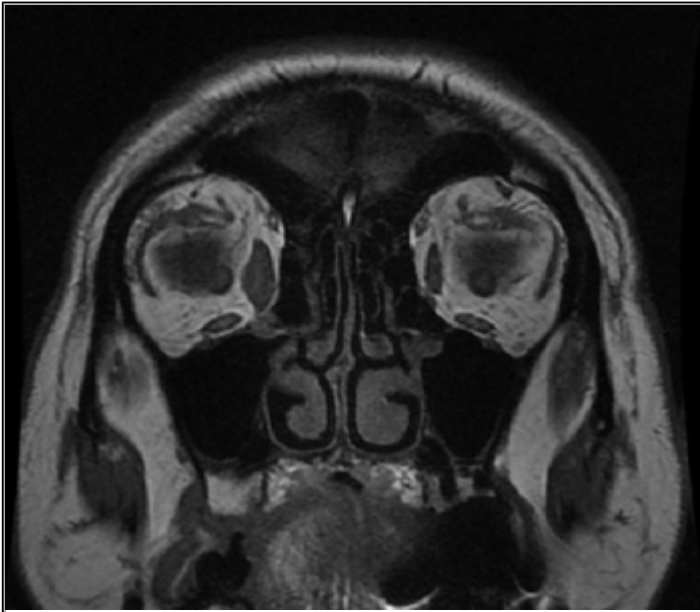


CT-coronal image. A marked thickening of the internal rectus muscle of the right orbit is seen.

© ACIM, Hospital Universitario y Politécnico La Fe, Valencia, Spain.

Area of Interest: Head and neck;
Imaging Technique: CT;
Procedure: Contrast agent-intravenous;
Special Focus: Lymphoma;

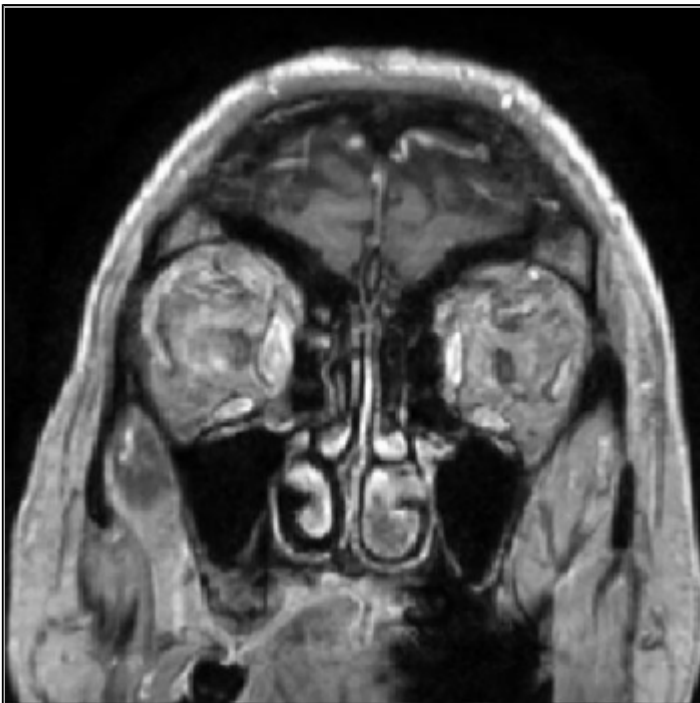
Figure 2 Diagnostic orbital MRI



T1-weighted image showed thickened medial rectus muscle with isointens signal.

© ACIM, Hospital Universitario y Politécnico La Fe, Valencia, Spain.

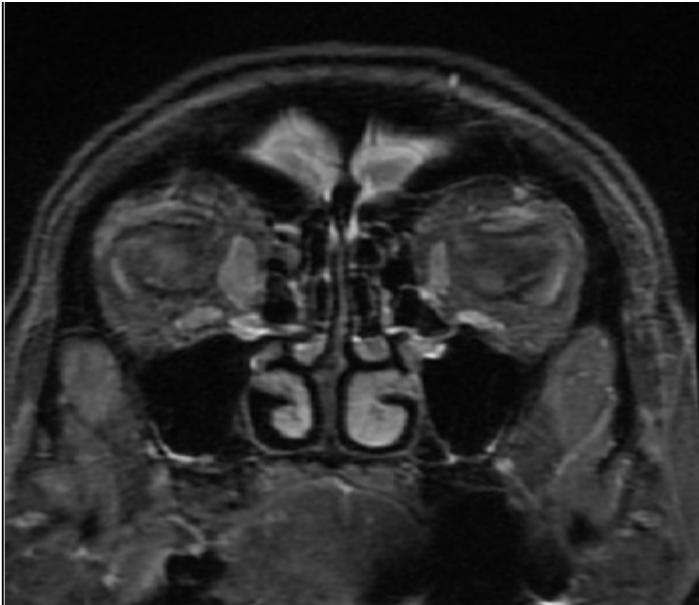
Area of Interest: Head and neck;
Imaging Technique: MR;
Procedure: Contrast agent-intravenous;
Special Focus: Lymphoma;



T1-weighted with gadolinium sequences showed an homogenous contrast enhancement.

© ACIM, Hospital Universitario y Politécnico La Fe, Valencia, Spain.

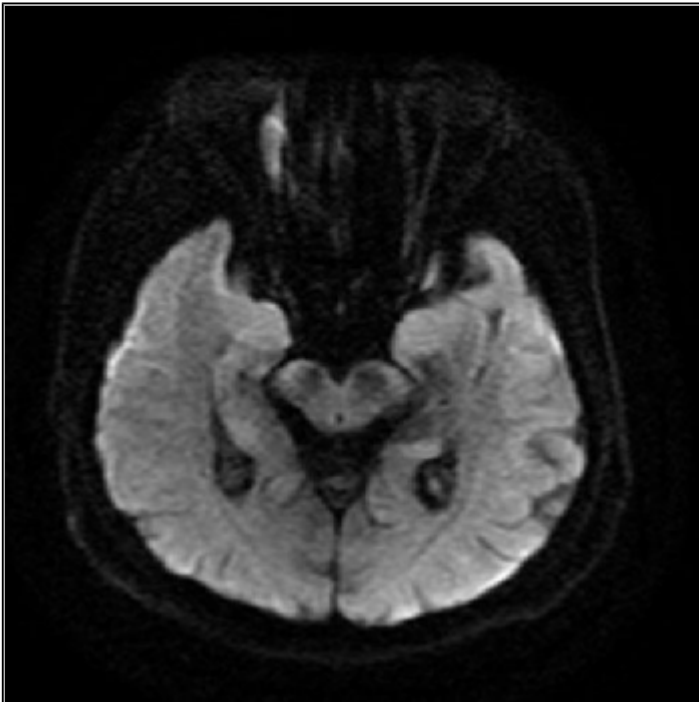
Area of Interest: Head and neck;
Imaging Technique: MR;
Procedure: Contrast agent-intravenous;
Special Focus: Lymphoma;



STIR coronal image showed thickened medial rectus muscle with isointens signal.

© ACIM, Hospital Universitario y Politécnico La Fe, Valencia, Spain.

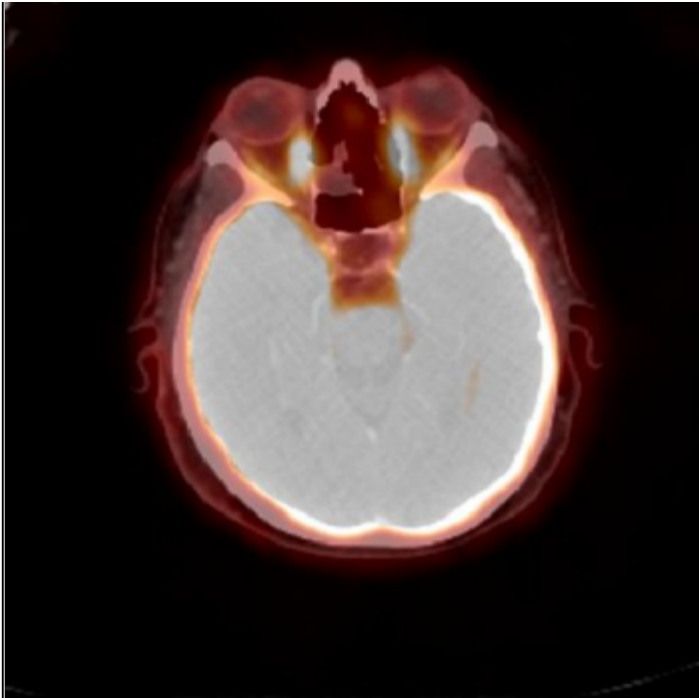
Area of Interest: Head and neck;
Imaging Technique: MR;
Procedure: Contrast agent-intravenous;
Special Focus: Lymphoma;



Restricted diffusion of the medial rectus muscle is seen

© ACIM, Hospital Universitario y Politécnico La Fe, Valencia, Spain.

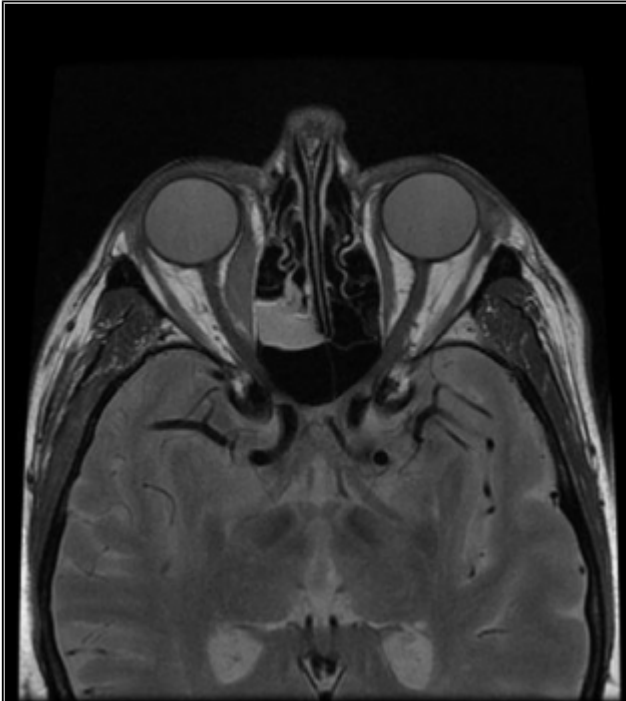
Area of Interest: Head and neck;
Imaging Technique: MR;
Procedure: Contrast agent-intravenous;
Special Focus: Lymphoma;



FDG PET-CT image. A fusiform thickening of the medial rectus muscle was observed.

© ACIM, Hospital Universitario y Politécnico La Fe, Valencia, Spain.

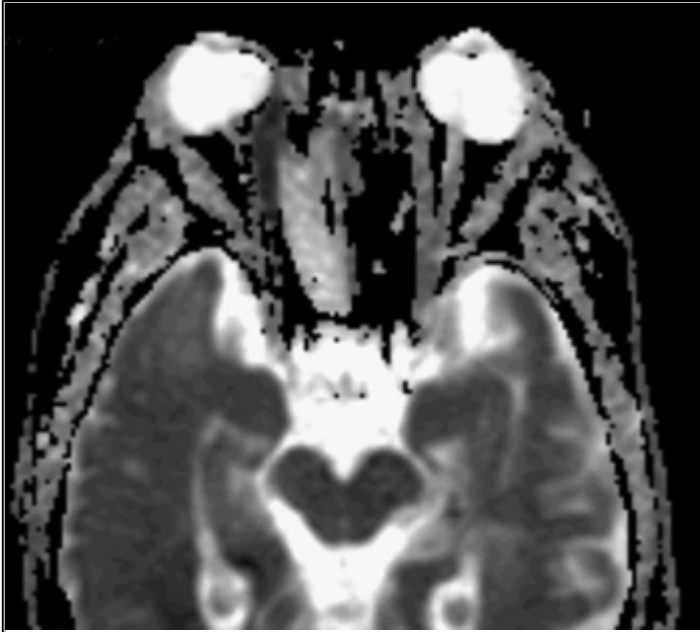
Area of Interest: Head and neck;
Imaging Technique: PET-CT;
Procedure: Diagnostic procedure;
Special Focus: Lymphoma;



T2-weighted image showed thickened muscle with isointens signal.

© ACIM, Hospital Universitario y Politécnico La Fe, Valencia, Spain.

Area of Interest: Management;
Imaging Technique: MR;
Procedure: Imaging sequences;
Special Focus: Lymphoma;

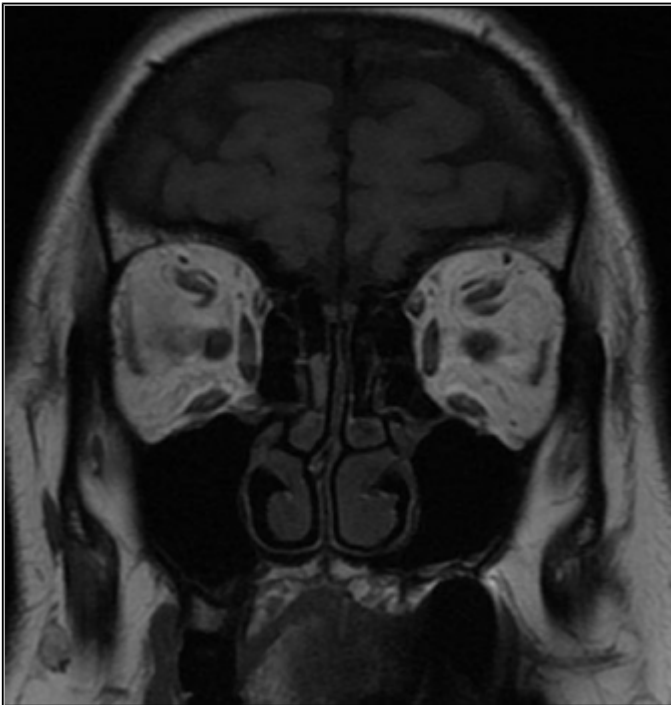


ADC map that shows a very low signal for the affected muscle compared with the other structures.

© ACIM, Hospital Universitario y Politécnico La Fe, Valencia, Spain.

Area of Interest: Head and neck;
Imaging Technique: MR;
Procedure: Imaging sequences;
Special Focus: Lymphoma;

Figure 3 After treatment

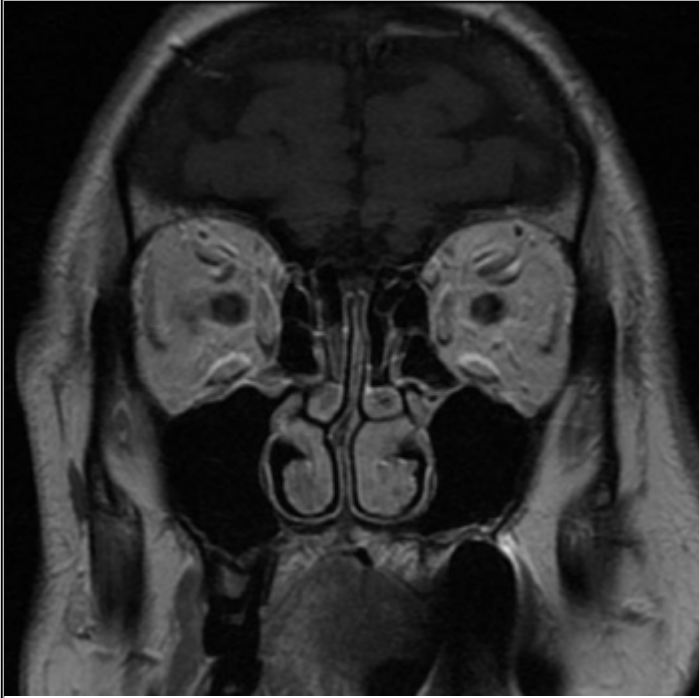


Normal T1 weighted coronal image.

© ACIM, Hospital Universitario y Politécnico La Fe, Valencia, Spain.

Area of Interest: Head and neck;
Imaging Technique: MR;

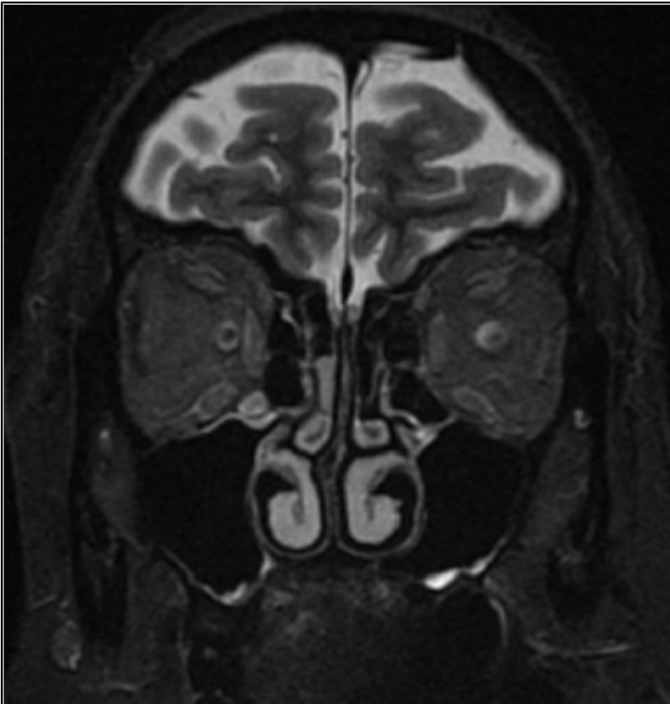
Procedure: Diagnostic procedure;
Special Focus: Lymphoma;



T1 weighted images with gadolinium. Normal enhancement after contrast administration of all the orbita structures.

© ACIM, Hospital Universitario y Politécnico La Fe, Valencia, Spain.

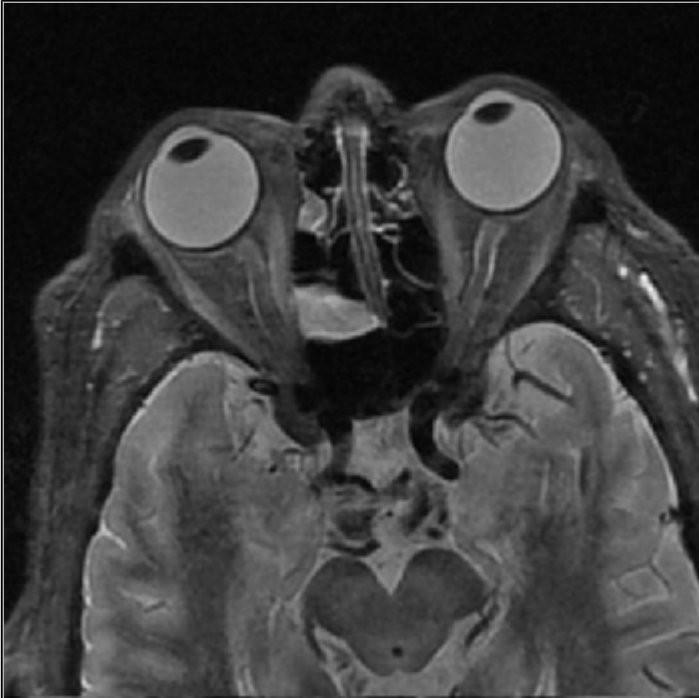Area of Interest: Head and neck;
Imaging Technique: MR;
Procedure: Diagnostic procedure;
Special Focus: Lymphoma;



Normal STIR coronal image

© ACIM, Hospital Universitario y Politécnico La Fe, Valencia, Spain.

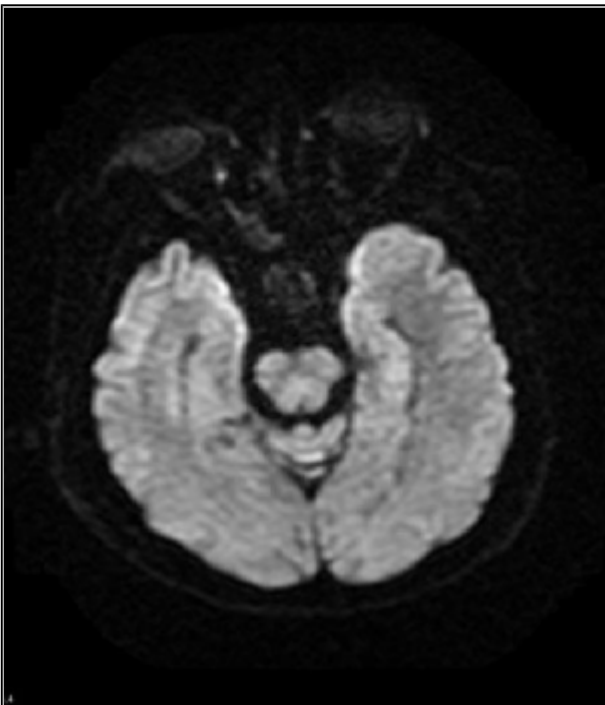
Area of Interest: Head and neck;
Imaging Technique: MR;
Procedure: Diagnostic procedure;
Special Focus: Lymphoma;



Normal STIR axial image

© ACIM, Hospital Universitario y Politécnico La Fe, Valencia, Spain.

Area of Interest: Head and neck;
Imaging Technique: MR;
Procedure: Diagnostic procedure;
Special Focus: Lymphoma;



DWI axial image. No alteration of the diffusion is seen.

© ACIM, Hospital Universitario y Politécnico La Fe, Valencia, Spain.

Area of Interest: Head and neck;
Imaging Technique: MR;
Procedure: Imaging sequences;
Special Focus: Lymphoma;

References

- [1] Sarah N. Khan, MD ; Ali R. Sepahdari, MD (2012) Orbital masses: CT and MRI of common vascular lesions, benign tumors, and malignancies Saudi J Ophthalmol 26(4): 373-383
- [2] Dilek Gokharman , Sonay Aydin (2018) Magnetic Resonance Imaging in Orbital Pathologies: A Pictorial Review J Belg Soc Radiol 101(1): 5
- [3] Tailor TD1, Gupta D, Dalley RW, Keene CD, Anzai Y. (2013) Orbital neoplasms in adults: clinical, radiologic, and pathologic review. Radiographics 33(6):1739-58
- [4] LeBedis CA, Sakai O (2008) Nontraumatic Orbital Conditions: Diagnosis with CT and MR Imaging in the Emergent Setting Radiographics 28(6):1741-53
- [5] Ferreri AJ1, Dolcetti R, Du MQ, Doglioni C, Resti AG, Politi LS, De Concilliis C, Radford J, Bertoni F, Zucca E, Cavalli F, Ponzoni M. (2008) Ocular adnexal MALT lymphoma: An intriguing model for antigen-driven lymphomagenesis and microbial-targeted therapy Ann Oncol 19(5):835-46
- [6] Politi et al (2010) Ocular Adnexal Lymphoma: Diffusion-weighted MR Imaging for Differential Diagnosis and Therapeutic Monitoring Radiology 256-2

Citation

Oprisan AAI ¹, Barreda-Solana M ¹, Diaz-Cespedes RA ², Piqueras-Olmeda R ¹

¹ Radiology Service, Hospital Universitario y Politécnico La Fe, Valencia, Spain.

² Ophthalmology Service, Hospital Manises, Valencia, Spain.

Hospital Universitario y Politécnico La Fé; Av. Fernando Abril Martorell, 106 Torre E, Planta 0, Despacho CEIB 46026 Valencia, Spain; Email:oprisan.anca@gmail.com (2018, Oct. 21)

Infiltration of the medial rectus muscle as the first manifestation in a primary orbital lymphoma {Online}

URL: <http://www.eurorad.org/case.php?id=16041>