



## Ultrasonographic evaluation of cross-sectional area of tarsal ligaments in Standardbred Trotter Horses

Giuseppe Spinella, Simona Valentini, Lidia Pitti, Jose Maria Carrillo, Monica Rubio, Joaquín Sopena, Angelo Santana & Jose Manuel Vilar

To cite this article: Giuseppe Spinella, Simona Valentini, Lidia Pitti, Jose Maria Carrillo, Monica Rubio, Joaquín Sopena, Angelo Santana & Jose Manuel Vilar (2018) Ultrasonographic evaluation of cross-sectional area of tarsal ligaments in Standardbred Trotter Horses, Journal of Applied Animal Research, 46:1, 915-919, DOI: [10.1080/09712119.2018.1431241](https://doi.org/10.1080/09712119.2018.1431241)

To link to this article: <https://doi.org/10.1080/09712119.2018.1431241>



© 2018 The Author(s). Published by Informa UK Limited, trading as Taylor & Francis Group



Published online: 30 Jan 2018.



Submit your article to this journal [↗](#)



Article views: 150



View Crossmark data [↗](#)

## Ultrasonographic evaluation of cross-sectional area of tarsal ligaments in Standardbred Trotter Horses

Giuseppe Spinella<sup>a</sup>, Simona Valentini<sup>a</sup>, Lidia Pitti<sup>b</sup>, Jose Maria Carrillo<sup>c</sup>, Monica Rubio<sup>c</sup>, Joaquín Sopena<sup>c</sup>, Angelo Santana<sup>d</sup> and Jose Manuel Vilar<sup>b,e</sup>

<sup>a</sup>Department of Veterinary Medical Sciences, University of Bologna, Ozzano dell'Emilia (BO), Italy; <sup>b</sup>Animal Pathology Department, Faculty of Veterinary Medicine, University of Las Palmas de Gran Canaria, Trasmontaña, Arucas, Spain; <sup>c</sup>Department of Medicina y Cirugía Animal, University of CEU Cardenal Herrera, Cátedra García Cugat, Valencia, Spain; <sup>d</sup>Mathematics Department, University of Las Palmas de Gran Canaria, Tafira, Las Palmas de Gran Canaria, Spain; <sup>e</sup>Instituto Universitario de Investigaciones Biomédicas y Sanitarias, Animal Pathology Department, Universidad de Las Palmas de Gran Canaria, Las Palmas, Spain

### ABSTRACT

Ultrasound evaluations of the cross-sectional area (CSA) in the tarsal region of Standardbred Trotter Horses (STH) have been previously reported for tendons but not for ligaments. The objective of this study was to identify normal ultrasonographic CSAs in the tarsal ligaments of STH. Transverse echographic scans of ligaments at five tarsal levels from proximal to distal direction were recorded in 25 healthy STH. All images were recorded, and the CSA measurements (mean  $\pm$  SD) were determined. The widest structure resulted in the long plantar ligament (LPL) at distal portion of the astragalus, and the smallest was the long medial collateral ligament (LMCL) at the medial malleolus of the tibia. Long collateral ligaments (LCL) increased their CSA at the level of their distal insertions, while LPL reached the maximum CSA in the middle of its length. Although this report was limited due to its retrospective design, it is the opinion of the authors that the normal CSAs investigated in this paper could function as a reference guide when tarsal pathological conditions are suspected in STH.

### ARTICLE HISTORY

Received 6 June 2017  
Accepted 13 January 2018

### KEYWORDS

Equine; ligament; cross-sectional area; tarsus; Standardbred Trotter Horses

## 1. Introduction

Ultrasonographic techniques in the diagnosis of limb soft tissue lesions in horses have been widely investigated in sports veterinary medicine. Echogenic evaluations of equine tendon and ligament texture and size have been described in order to recognize disorders in both adult horses and foals, particularly within the palmar metacarpal regions (Biller and Myer 1989; Chhem et al. 1994; Smith et al. 1994; Gillis et al. 1997; Reef et al. 2004; Agut et al. 2009; Korosue et al. 2015; Spinella et al. 2015; El-Shafaey et al. 2016; Spinella et al. 2016). Likewise, ultrasound investigations of tendon and ligament aspects within the tarsal region have been previously reported (Ruohoniemi 1993; Santschi et al. 1993; Tomlison et al. 2000; Reef et al. 2004; Raes et al. 2010; Vilar et al. 2011).

The relevance of ultrasound investigations of the cross-sectional area (CSA) has been reported for palmar metacarpal tendons and ligaments in sound horses of different breeds (Wood et al. 1993; Gillis et al. 1995a,b, 1997; Agut et al. 2009; Korosue et al. 2015), but few research studies have been done regarding specific musculoskeletal injuries in STH (Bertuglia et al. 2014). In fact, no data regarding the CSAs of tarsal ligaments of Standardbred Trotter Horses (STH) have been previously published.

Tarsal ligament injuries, such as desmitis of the tarsocrural joint, are often clinically underestimated, which, if not properly diagnosed, can cause severe lameness in horses. Tarsal

ligament injuries could be more easily diagnosed with an increase in CSA ultrasonographs, among other signs (Lamb et al. 2012). For this reason, the assessment of normal CSA measurements of tarsal ligaments could be useful for ultrasonography practitioners in order to diagnosis certain injuries in STH.



The purpose of this study was to report the normal CSA of tarsal ligaments, including the long lateral collateral ligament (LLCL), the small lateral collateral ligament (SLCL), the long plantar ligament (LPL), the long medial collateral ligament (LMCL), and the small medial collateral ligament (SMCL) in STH.

## 2. Materials and methods

### 2.1. Animals

For this study, ultrasound records of sound client-owned STH examined during routine clinical trials (e.g. periodic deworming, etc.) were obtained within a 10-years timeframe (2003–2013). Inclusion criteria were as follows: (1) all animals were conditioned and competing (or had competed) in various race-courses; (2) a complete orthopaedic examination was performed in order to include only orthopedically sound horses; and (3) the tarsal region was ultrasonographically normal and completely examined. The horse owners signed an informed consent form to attend in the study.

Both tarsi of 25 healthy STH, 13 males and 12 females, met the inclusion criteria. Mean age was (mean  $\pm$  SD) 7.05  $\pm$  2.58

**CONTACT** Jose Manuel Vilar  [jose.vilar@ulpgc.es](mailto:jose.vilar@ulpgc.es)  Instituto Universitario de Investigaciones Biomédicas y Sanitarias, Animal Pathology Department, Universidad de Las Palmas de Gran Canaria, 35416, Trasmontaña S/N, Arucas, Las Palmas, Spain

© 2018 The Author(s). Published by Informa UK Limited, trading as Taylor & Francis Group

This is an Open Access article distributed under the terms of the Creative Commons Attribution License (<http://creativecommons.org/licenses/by/4.0/>), which permits unrestricted use, distribution, and reproduction in any medium, provided the original work is properly cited.

years; height was  $160.18 \pm 2.54$  cm. Thoracic and tarsal perimeters were  $181.33 \pm 2.80$  cm and  $41.20 \pm 0.64$  cm, respectively. No significant differences among the considered variables were observed between males and females nor between right and left hindlimbs ( $p$ -value  $> 0.05$  in all cases). For this reason, all tarsi were considered as a unique group, independent from sex and laterality. For each one of investigated ligaments, confidence intervals were reported at 95% for normal values.

## 2.2 . Ultrasound examination

A real-time ultrasound scanner (Toshiba Nemio, Milano, Italy) with a 7.5 MHz sector probe and a standoff pad were used for all ultrasound examinations in order to improve ligament visualization. Sedation was obtained with detomidine ( $60 \mu\text{g}/\text{kg}$  bw IM, Domosedan – Pfizer, Madrid, Spain).

Skin and hair of the tarsal region were cleaned with soap, warm water, and ethyl alcohol; the hair was not shaved. Ultrasonographic examination was performed with horses in a weight-bearing standing position, except for images taken for the short collateral ligaments (SCL). In order to move away from superficial structures and obtain better visualization, images of the SCL were taken with the joint flexed.

As previously reported (Valentini et al. 2005; Vilar et al. 2008), different reference levels were identified: the 4 cm proximally to the point of the hock (level 0); the point of the hock (level 1); the medial malleolus of the tibia (level 2); the distal aspect of the trochlea of the astragalus (level 3); and the base of the 2nd metatarsal bone (level 4). Transverse scans relative to each studied ligament were performed at each level along the four sides (lateral, medial, dorsal, and plantar) of each tarsus to get the CSA measurements of the LLCL, the SLCL, the LPL, the LMCL, the SMCL, and their portions, if detected (Figure 1). The ultrasound examination was performed by a single operator (JMV, who has 15 years of experience in equine ultrasound examination). All methods were completed in accordance with the recommendations of Animal Care and Ethics Committees of the Universities of Bologna (Italy) and Las Palmas de Gran Canaria (Spain).

## 2.3 . Image analysis

In the digitized images, the CSA was calculated using appropriate software (Metric, PCE GmbH, Dietmannsried, Germany). Maximum accuracy was achieved by outlining with a precision tablet pen (Wacom Europe, Krefeld, Germany). This measurement was performed by three different researchers (GS, LP, SV) blind to each other, and the median value of the three measurements was considered as long as the measurements differed  $<10\%$ . When the difference was  $>10\%$ , new measurements were obtained (Agut et al. 2009). Area was expressed in  $\text{cm}^2$ .

## 2.4 . Statistics

Statistical analysis was conducted as previously reported for tarsal tendons (Vilar et al. 2011). A Student  $t$  test was used to analyse the tarsal thoracic perimeter (circumference), the height between males and females, and to test the influence of laterality (right and left hindlimb) on CSAs. Values of

**Table 1.** Cross-sectional area (mean  $\pm$  SD), minimum and maximum observed values, 95% lower and upper values of confidence interval, and Shapiro-Wilk (SW) value for each structure at the relevant level/s.

Ligament (level)	Mean $\pm$ SD	Min	Max	Lower value	Upper value	SW
LLCL (2)	0.58 0.05L	0.48	0.70	0.47	0.69	0.88
LLCL (3)	0.75 0.08L	0.60	0.92	0.59	0.92	0.88
SLCLs (2)	0.25 0.03L	0.20	0.30	0.19	0.31	0.65
SLCLm (2)	0.25 0.03L	0.20	0.30	0.19	0.31	0.65
SLCLd (2)	0.35 0.03L	0.30	0.40	0.29	0.41	0.65
LPL (2)	1.14 0.05P	1.05	1.28	1.04	1.25	0.53
LPL (3)	1.17 0.05P	1.08	1.30	1.07	1.28	0.70
LPL (4)	1.10 0.03P	1.04	1.20	1.03	1.18	0.36
LMCL (2)	0.39 0.05M	0.30	0.51	0.29	0.50	0.82
LMCL (3)	0.59 0.06M	0.48	0.72	0.47	0.71	0.85
SMCLs (2)	0.29 0.06M	0.20	0.40	0.17	0.41	0.65
SMCLm (2)	0.45 0.03M	0.40	0.50	0.39	0.51	0.65

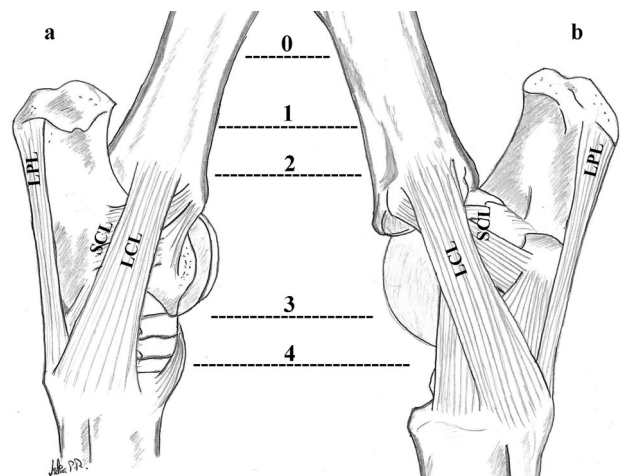
Units:  $\text{cm}^2$ . In column n.1: LLCL = Long lateral collateral ligament; SLCL = small lateral collateral ligament; LPL = long plantar ligament; LMCL = long medial collateral ligament; SMCL = small medial collateral ligament. s = superficial portion; m = median portion; d = deep portion. In column n.2: L = lateral aspect of the tarsus; P = plantar aspect of the tarsus; M = medial aspect of the tarsus.

$p \leq 0.05$  were accepted as significant for all tests. For each of the investigated ligaments, a mean value ( $\text{cm}^2$ )  $\pm$  standard deviation (SD), minimum and maximum values were recorded (Table 1). For normally distributed variables, the confidence interval was set at 95%. Normality was analyzed using the Shapiro–Wilk test.

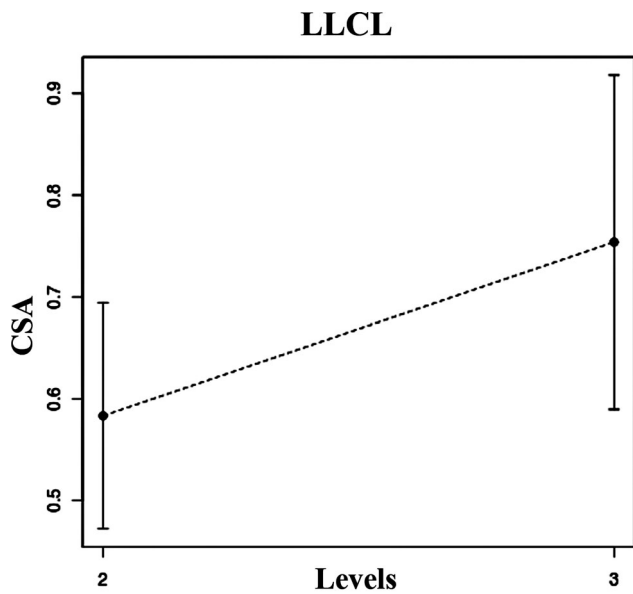
## 3. Results

CSA measurements for each ligament are summarized in Table 1. The results showed the CSA of the LLCL increasing from level 2 to level 3 (Figure 2). The three portions (superficial, median, and deep) of the SLCL were detectable only at level 2. Deep portion appeared to always be the largest (Figure 3).

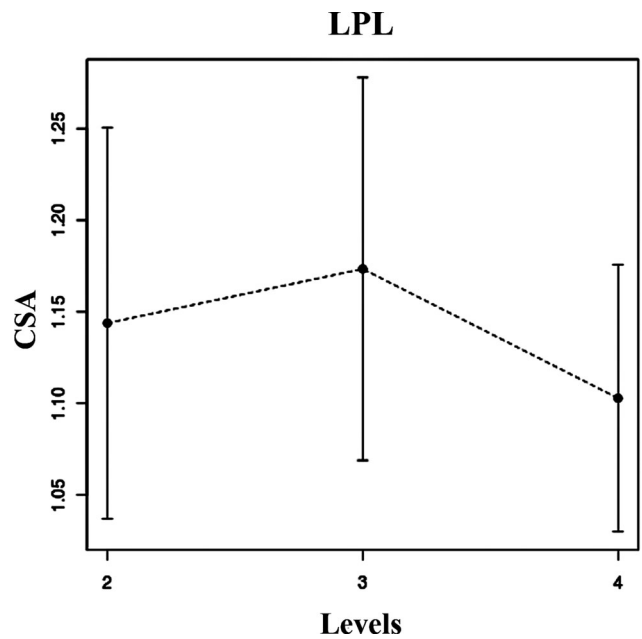
The LPL was the largest ligamentous structure among those investigated and was easily detected from level 2 to level 4. Even if the CSA of this structure minimally increased from level 2 to level 3, it significantly decreased from level 3 to level 4 (Figure 4). The LMCL was identified from level 2 to



**Figure 1.** Tarsal lateral (a) and medial (b) illustration showing approximately the reference levels for obtaining the ultrasonographic images. Note that these images were obtained transversely to the studied ligament. Note also that echographies of short ligaments were obtained with the hock in flexion. LPL: long plantar ligament; LCL: long collateral ligaments; SCL: short collateral ligaments.



**Figure 2.** Mean values and acceptance intervals of the cross-sectional area (CSA) in cm<sup>2</sup> at each level of the long lateral collateral ligament (LLCL).



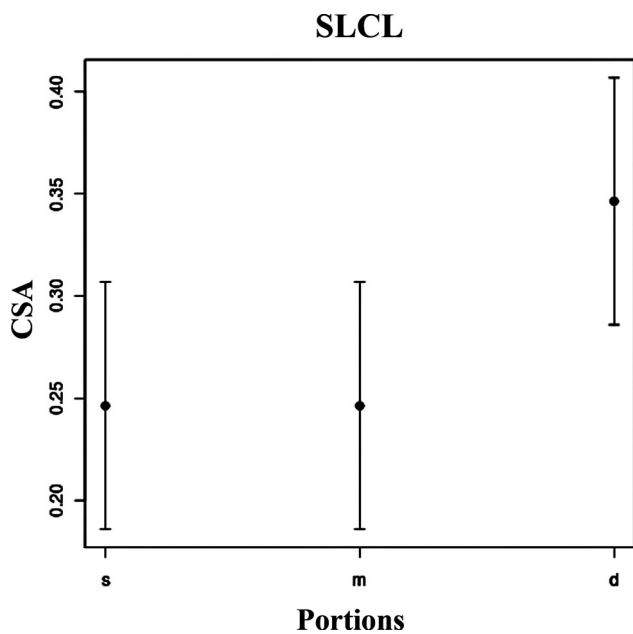
**Figure 4.** Mean values and acceptance intervals of the cross-sectional area (CSA) in cm<sup>2</sup> at each level of the long plantar ligament (LPL).

level 3 (Figure 5). Although the LMCL is the smallest among those examined, this ligament also widened distally at the LLCL. Superficial and median portions of the SMCL could be detected in all horses, while deep portion was only observed in two cases and showed similar CSAs (Figure 6).

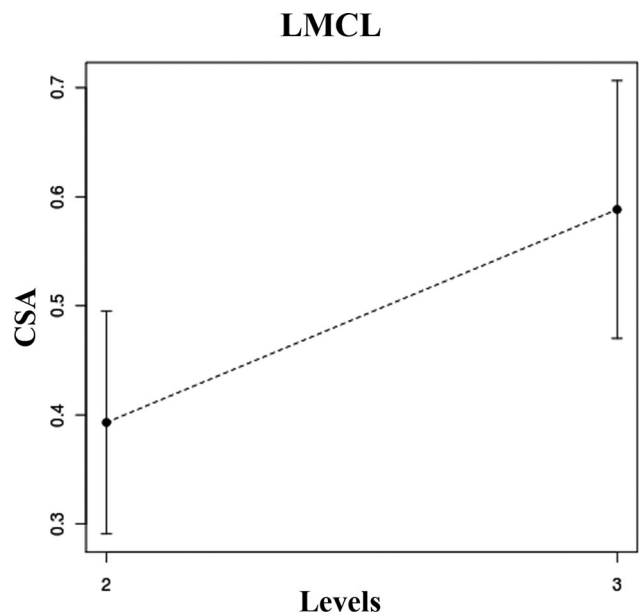
#### 4. Discussion

CSAs of the tarsal ligaments of STH were obtained to create reference measurements, which could be useful in clinical investigations. Although no references had yet been reported for STH to the authors' knowledge, changes in CSA, along

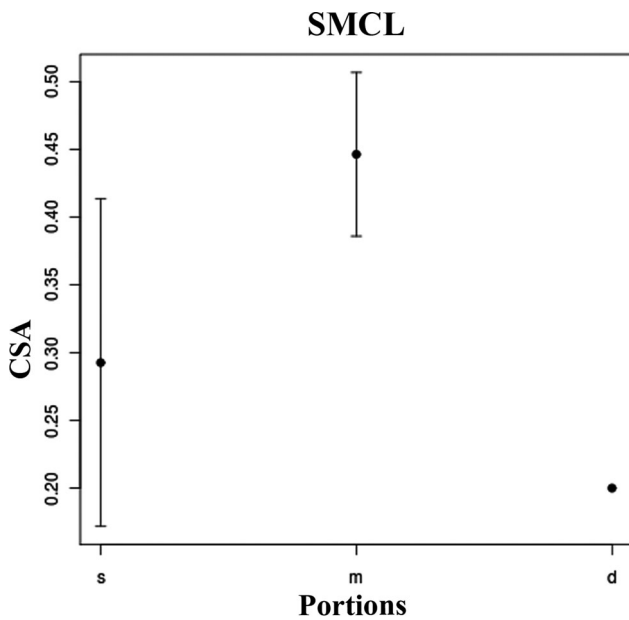
with other parameters, have been widely used for the ultrasonographic diagnosis of injuries (Pickersgill et al. 2001; Agut et al. 2009; Vilar et al. 2011). Ultrasonographic evaluation of the CSA measurements in forelimb tendinous structures (i.e. superficial and deep digital flexor tendons) have proven to be an useful method for non-invasive tendon assessment (Smith et al. 1994; Gillis et al. 1995a; Pickersgill et al. 2001; Perkins et al. 2004; Agut et al. 2009; Raes et al. 2010; Korosue et al. 2015). Quantitative ultrasound parameters had increased their application in equine clinical practice, and CSA analysis has become an useful technique for non-invasive assessments of tendons and ligaments, even if inter-breed variations have



**Figure 3.** Mean values and acceptance intervals of the cross-sectional area (CSA) in cm<sup>2</sup> at the superficial (s), median (m), and deep (d) portion of the small lateral collateral ligament (SLCL).



**Figure 5.** Mean values and acceptance intervals of the cross-sectional area (CSA) in cm<sup>2</sup> at each level of the long medial collateral ligament (LMCL).



**Figure 6.** Mean values and acceptance intervals of the cross-sectional area (CSA) in  $\text{cm}^2$  at the superficial (s), median (m) and deep (d) portion of the small lateral collateral ligament (SMCL).

been proven (Wood et al. 1993; Gillis et al. 1995b; Agut et al. 2009; Vilar et al. 2011; Korosue et al. 2015; Spinella et al. 2015, 2016).

The technical features (advantages and limitations) of linear or sector ultrasound probes were well known (Reef 1998; Agut et al. 2009). In a majority of cases, probe selection was mostly based on the experience and availability of the operator (Agut et al. 2009). Our decision to use a sector probe was primarily related to the highly irregular surface of the tarsus, and the difficulty to create a suitable contact between the skin and the linear probe along each ligamentous structure. However, the use of a fitting standoff pad could minimize the incidence artifacts, providing a better adaptation of the probe to the investigated region.

Limb position (lifted or in weight-bearing position) could also condition the CSA measurements, even if these differences have not been completely described for tarsus ligaments. Changes in tension echographic patterns have been reported by other authors in forelimbs as a feature that could be mistaken with injuries (Nicoll et al. 1993; Gillis et al. 1995b; Mickelthwaite et al. 2001). In order to avoid any CSA variation, all scans were performed with the limbs in the weight-bearing position.

The absence of significant differences in height at the withers, along with thoracic and tarsal perimeters, between males and females led us to suppose that differences did not exist between ligaments as well. Moreover, as observed in our horses, several studies proved that differences between the right and left limbs of adult horses and foals for quantitative ultrasound parameters were not statistically significant (Gillis et al. 1995a; Agut et al. 2009; Spinella et al. 2015, 2016). Therefore, the variable *laterality* has been currently discarded in equine studies (Birch et al. 1999).

The training programme for each horse was another variable that could lead to anatomical structure modification for

adaptive hypertrophic changes in the matrix composition, resulting in an increase of ligament CSA, which was assumed to be consistent throughout the life of the horse (Cherdchutham et al. 2001; Kasashima et al. 2002; Moffat et al. 2008; Dyson et al. 2017). For this reason, horses that follow or had followed the same training were selected. All horses in the present study had raced regularly in trotting competitions during or before the clinical trial period to ensure a homogeneity of this variable. Moreover, based on the assumption that CSA values remained consistent over the life of the horse and that these horses had a highly specific purpose (trotting), CSA values could remain unchanged even if these horses were not conditioning or competing at the time of examination.

Regarding the evaluation of ligamentous CSA measures across the tarsus, we found that two of the three long ligaments (LMCL and LCLL) increased their CSA distally, which could be due to their enlargement in reaching the bone insertions. The LPL, instead, becomes thinner distally. Relating to short ligaments, which could be measured only at level 2, the median portion of the SMCL appeared to be the largest, although this structure could not be echographically differentiated from the deep portion, which is contrary to what occurs in the SLCL. For this reason, in our opinion, the value of median portion of SMCL could represent the sum of median and deep portions.

This study has some limitations. (1) The study has a retrospective nature. (2) A higher frequency probe might be more suitable for superficial structures, although previously successful results obtained from this region prompted us to use a 7.5 MHz probe (Vilar et al. 2011). (3) The results of this study were obtained only from conditioned STH; therefore, we cannot account for the values for other breeds and extrapolations should be made cautiously. (4) Other quantitative ultrasound parameters (mean and relative echogenicities and fiber alignment) were not investigated, but they were not out of the aim of this study. Thus, this report should encourage other researchers to confirm our results with a further prospective investigation and to provide other ultrasound quantitative parameters.

## 5. Conclusion

The results from the CSA measurements of tarsal ligaments (LLCL, SLCL, LPL, LMCL, and SMCL) from this study could be used as comparative reference values to assist sonographers investigating pathological changes in STH.

## Acknowledgments

The authors gratefully acknowledge the equine owners for their cooperation and Mrs Elizabeth Sus Carter for her assistance in English language revision.

## Disclosure statement

No potential conflict of interest was reported by the authors.

## References

- Agut A, Martínez ML, Sánchez-Valverde MA, Soler M, Rodríguez MJ. 2009. Ultrasonographic characteristics (cross-sectional area and relative



- echogenicity) of the digital flexor tendons and ligaments of the metacarpal region in Purebred Spanish horses. *Vet J.* 180:377–383.
- Bertuglia A, Bullone M, Rossotto F, Gasparini M. 2014. Epidemiology of musculoskeletal injuries in a population of harness Standardbred racehorses in training. *BMC Vet Res.* 10:11.
- Biller DS, Myer W. 1989. Ultrasound scanning of superficial structures using an ultrasound standoff pad. *Vet Radiol.* 29:138–142.
- Birch HL, McLaughlin L, Smith RK, Goodship AE. 1999. Treadmill exercise-induced tendon hypertrophy: assessment of tendons with different mechanical functions. *Equine Vet J.* 30:222–226.
- Cherdchutham W, Meershoek L, van Weeren PR, Barneveld A. 2001. Effects of exercise on biomechanical properties of the superficial digital flexor tendon in foals. *Am J Vet Res.* 62:1859–1864.
- Chhem RK, Kaplan PA, Dussault RG. 1994. Ultrasonography of the musculoskeletal system. *Radiol Clin North Am.* 32:275–289.
- Dyson S, Blunden A, Murray R. 2017. Magnetic resonance imaging, gross postmortem, and histological findings for soft tissues of the plantar aspect of the tarsus and proximal metatarsal region in non-lame horses. *Vet Radiol Ultrasound.* 58:216–227.
- El-Shafaey A, Zaghoul M, Abou-Alsaud G, Karrouf E. 2016. Assessment of digital flexors tenorrhaphy in equine: a review. *J Appl An Res.* 44:201–209.
- Gillis C, Meagher DM, Cloninger A, Locatelly L, Willis N. 1995a. Ultrasonographic cross-sectional area and mean echogenicity of the superficial and deep digital flexor tendons in 50 trained thoroughbred racehorses. *Am J Vet Res.* 56:1265–1269.
- Gillis C, Pool RR, Meagher DM, Stover SM, Reiser K, Willits N. 1997. Effect of maturation and ageing on the histomorphometric and biochemical characteristics of equine superficial digital flexor tendon. *Am J Vet Res.* 58:425–430.
- Gillis C, Sharkey N, Stover SM, Pool RR, Meagher DM, Willits N. 1995b. Ultrasonography as a method to determine tendon cross-sectional area. *Am J Vet Res.* 56:1270–1274.
- Kasashima Y, Smith RK, Birch HL, Takahashi T, Kusano K, Goodship AE. 2002. Exercise-induced tendon hypertrophy: cross-sectional area changes during growth are influenced by exercise. *Equine Vet J.* 34:264–268.
- Korosue K, Endo Y, Murase H, Ishimaru M, Nambo Y, Sato F. 2015. The cross-sectional area changes in digital flexor tendons and suspensory ligament in foals by ultrasonographic examination. *Equine Vet J.* 47:548–552.
- Lamb L, Zubrod C, Hague B, Brakenhoff J. 2012. Major clinical outcome of collateral ligament injuries of the tarsus. *Can Vet J.* 53:518–524.
- Micklethwaite L, Wood AK, Sehgal CM, Polansky M, Dowling BA, Dart AJ, Rose RJ, Hodgson DR. 2001. Use of quantitative analysis of sonographic brightness for detection of early healing of tendon injury in horses. *Am J Vet Res.* 62:1320–1327.
- Moffat PA, Firth EC, Rogers CW, Smith RK, Barneveld A, Goodship AE, Kawcak CE, McIlwraith CW, van Weeren PR. 2008. The influence of exercise during growth on ultrasonographic parameters of the superficial digital flexor tendon of young Thoroughbred horses. *Equine Vet J.* 40:136–140.
- Nicoll RG, Wood AK, Martin IA. 1993. Ultrasonographic observations of the flexor tendons and ligaments of the metacarpal region of horses. *Am J Vet Res.* 54:502–506.
- Perkins NR, Rogers CW, Firth EC, Anderson BH. 2004. Musculoskeletal responses of 2-year-old Thoroughbred horses to early training. 3. In vivo ultrasonographic assessment of the cross-sectional area and echogenicity of the superficial digital flexor tendon. *N Z Vet J.* 52:280–284.
- Pickersgill CH, Marr CM, Reid SW. 2001. Repeatability of diagnostic ultrasonography in the assessment of the equine superficial digital flexor tendon. *Equine Vet J.* 33:33–37.
- Raes EV, Vanderperren K, Pille F, Saunders JH. 2010. Ultrasonographic findings in 100 horses with tarsal region disorders. *Vet J.* 186:201–209.
- Reef VB. 1998. *Equine diagnostic ultrasound.* Philadelphia: WB Saunders Company; p. 1–23.
- Reef VB, Whittier M, Allam L. 2004. *Joint ultrasonography clinical techniques.* Equine Practice. 3:256–267.
- Ruohoniemi M. 1993. Use of ultrasonography to evaluate the degree of ossification of the small tarsal bones in 10 foals. *Equine Vet J.* 25:539–543.
- Santschi EM, Adams SB, Fessler JF. 1993. Treatment of lesions of the sustentaculum of the calcaneus accompanied by tarsal sheath synovitis. *Proc Am Assoc Equine Pract.* 39:235–236.
- Smith RK, Jones R, Webbon PM. 1994. The cross-sectional areas of normal equine digital flexor tendons determined ultrasonographically. *Equine Vet J.* 26:460–465.
- Spinella G, Britti D, Loprete G, Musella V, Romagnoli N, Vilar J, Valentini S. 2016. Relative echogenicity of tendons and ligaments of the palmar metacarpal region in foals from birth to 4 months of age: a longitudinal study. *PLoS ONE.* 21. doi:10.1371/journal.pone.0159953
- Spinella G, Loprete G, Castagnetti C, Musella V, Antonelli C, Vilar JM, Britti D, Capitani O, Valentini S. 2015. Evaluation of mean echogenicity of tendons and ligaments of the metacarpal region in neonatal foals: A preliminary study. *Res Vet Sci.* 101:11–14.
- Tomlinson JE, Redding WR, Sage A. 2000. Ultrasonographic evaluation of tarsocrural joint cartilage in normal adult horses. *Vet Radiol Ultrasound.* 41:457–460.
- Valentini S, Vilar JM, Spinella G, Fedrigo M. 2005. Systematic ultrasonographic investigation of the equine tarsus. *Vet Res Comm.* 29:309–313.
- Vilar JM, Rivero MA, Arencibia A, Morales I, Pinedo M. 2008. Systematic exploration of the equine tarsus by ultrasonography. *Anat Histol Embryol.* 37:338–343.
- Vilar JM, Santana A, Espinosa J, Spinella G. 2011. Cross-sectional area of the tendons of the tarsal region in Standardbred Trotter Horses. *Equine Vet J.* 43:235–239.
- Wood AK, Sehgal CM, Polansky M. 1993. Sonographic brightness of the flexor tendons and ligaments in the metacarpal region of horses. *Am J Vet Res.* 54:1969–1974.